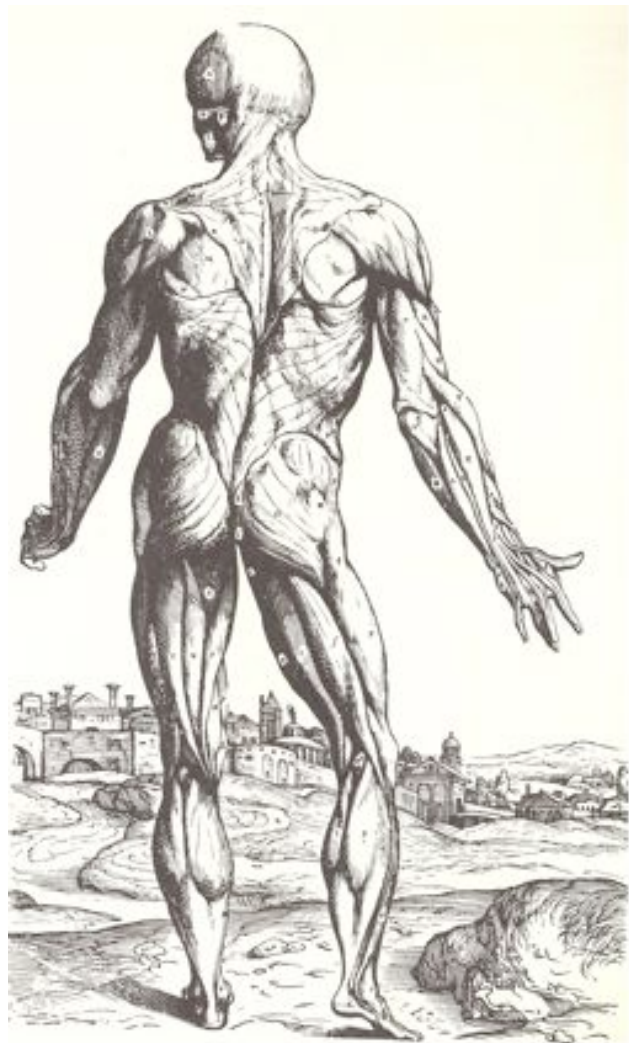



UNSW
THE UNIVERSITY OF NEW SOUTH WALES

Faculty of Medicine
School of Medical Sciences

ANAT2111 (& ANAT1551) Introductory Anatomy



Session 2 - 2014

Contents

Course convenor	2
Units of credit	2
Hours per week	2
What is anatomy?	2
Course aims	2
Student learning outcomes	2
Course relationships	3
Teaching rationale	4
Teaching strategies	4
Ethical behaviour and human remains	4
Anatomical terms	4
Assessment	5
Failure to sit a test	5
Resources for students	6
What is plagiarism?	6
Grievance procedures	7
Continual course improvement	7
Practical Class Attendance Requirement	7
Guidelines on extra-curricular activities affecting attendance	7
Health and Safety Rules for Students in the Dissecting Room	9
Course Lecture and Practical Class Schedule	12
Week 1: General Anatomy, General Skeletal System & Axial Bones	13
Week 2: Appendicular Bones & The Articular System	18
Week 3: General Muscular System, Axial & Upper Limb Muscles	22
Week 4: Lower Limb Muscles, General Nervous System & Brain	26
Week 5: Spinal Cord & Spinal Nerves	30
Week 6: Cranial Nerves & Autonomic Nervous System	33
Week 7: Eye & Ear	36
Revision Lab (11am-2pm or 2-5pm Thursday 11/09/2014)	40
Week 8: Spot Test No.1 (1-2pm or 2-3pm Wednesday 17/09/2014)	40
Week 9: Cardiovascular System	41
Week 10: Respiratory System	45
Week 11: Digestive System	48
Week 12: Urinary and Reproductive Systems	52
Week 13: Revision Lab (12-2pm or 2-4pm Tuesday 28/10/2014)	55
Spot Test No.2 (1-2pm or 2-3pm Wednesday 29/10/2014)	55

Cover illustration: One of the Vesalius plates (drawn by Calcar). From: Hixson, J. 1966. *The History of the Human Body*. Cooper Square Publishers, Inc.

Course convenor

Dr. Craig Hardman

Room 447, Wallace Wurth Building B27, UNSW, Sydney NSW 2052

Telephone: +61 2 9385 3569

E-mail: craig.hardman@unsw.edu.au

Units of credit

This course is worth six units of credit (6 UOC).

Hours per week

Five hours per week (5 HPW) comprising of two hours of lectures and three hours of laboratory time.

What is anatomy?

Anatomy literally means to break apart or separate the human body into its parts; to dissect the body. The earliest recorded anatomy teachers, Herophilus and Erasistratus, lived in Ancient Alexandria and taught anatomy between 300 BC and the second century AD. However, the roots of anatomy go back much further – perhaps 4,000 years ago – with the mummification practices of the Ancient Egyptians and with the Ancient Greek physicians. The most famous anatomist is the Ancient Roman Galen, whose work remained the standard for almost 1,300 years until the European Renaissance. During and after the Renaissance, anatomy developed into a modern scientific discipline. Therefore, anatomy is one of the oldest scientific fields and one that has always and continues to underpin medicine. It is also a well established scientific discipline in its own right.

Anatomy is a dynamic and diverse science that considers the structures of the body from the cellular level through to the body's external surface and beyond. Anatomy examines the cells and tissues of the body (cell biology and histology), the systems of the body (integumentary, skeletal, muscular, nervous, cardiovascular, lymphatic, respiratory, alimentary, urinary, genital and lymphoid systems), the joints, movements and biomechanics of the human body, human comparative and evolutionary anatomy (anthropology), the development of the embryo and postnatal growth of the infant and child, as well as clinical and radiographic anatomy. Anatomy at UNSW teaches and researches across most of these areas. Note that the term *gross anatomy* refers to the study of the structures of the body that are observable without the aid of microscopes (i.e. the naked eye) and which can be palpated (touched), while *microanatomy* is sometimes used to refer to the microscopic structures of the body (e.g. tissues; the subject of histology).

Course aims

The main aim of this course is to provide students with a solid foundation in the gross anatomy of the whole human body.

Student learning outcomes

Students should complete the course knowing (among other things):

1. *Practical laboratory skills in anatomy and an understanding of the ethics of working with human remains.*
2. *The basic plan of the human body; its major tissue types, body planes, spatial relations and movements.*
3. *Some general anatomical terms including common suffixes and prefixes.*
4. *The role and importance of the skeletal system, the names of major bones, and the names and functions of some major bony features.*
5. *The role and importance of the muscular system, the names of major muscles and muscle groups and their major functions.*
6. *Major types of joints in the human body and the basic structure of joints.*

7. *The role and importance of the central nervous system, its major functional divisions, the names and functions of its major components.*
8. *The major peripheral nerves and their main functions.*
9. *The role and importance of the cardiovascular system and the names and functions of its major components.*
10. *The role and importance of the respiratory system and the names and functions of its major components.*
11. *The role and importance of the digestive system and the names and functions of its major components.*
12. *The role and importance of the urinary system and the names and functions of its major components.*
13. *The role and importance of the reproductive systems and the names and functions of their major components (males and females).*
14. *The capacity to apply knowledge and to think critically within the anatomical sciences.*

The University of NSW has developed a list of attributes which its graduates should possess upon graduation (the 'graduate attributes'). The curriculum and assessment of this course have been designed to help students to develop these capabilities. Students completing the course will have gained knowledge and skills that contribute to directly to them acquiring these attributes during their study at UNSW. One way this has occurred is through curriculum mapping of this course.

For Science, the UNSW graduate attributes are as follows:

1. *Research, inquiry and analytical thinking abilities.* Technical competence and discipline specific knowledge. Ability to construct new concepts or create new understanding through the process of enquiry, critical analysis, problem solving, research and inquiry.
2. *Capability and motivation for intellectual development.* Capacity for creativity, critical evaluation and entrepreneurship. Ability to take responsibility for and demonstrate commitment to their own learning, motivated by curiosity and an appreciation of the value of learning.
3. *Ethical, Social and Professional Understanding.* Ability to critically reflect upon broad ethical principles and codes of conduct in order to behave consistently with a personal respect and commitment to ethical practice and social responsibility. Understanding of responsibility to contribute to the community. Respect and value social, multicultural, cultural and personal diversity.
4. *Communication.* Effective and appropriate communication in both professional (intra and inter disciplinary) and social (local and international) contexts.
5. *Teamwork, collaborative and management skills.* Ability to recognise opportunities and contribute positively to collaborative scientific research, and to perceive the potential value of ideas towards practical applications. Demonstrate a capacity for self management, teamwork, leadership and decision making based on open-mindedness, objectivity and reasoned analysis in order to achieve common goals and further the learning of themselves and others.
6. *Information literacy.* Ability to make appropriate and effective use of information and information technology relevant to their discipline.

Course relationships

ANAT2111 Introductory anatomy is the foundation course for all advanced (Level III) gross anatomy courses at UNSW: *Visceral Anatomy* (ANAT3121), *Functional Anatomy of the Head, Neck and Back* (ANAT3131), *Functional Anatomy of the Limbs* (ANAT3141) and *Neuroanatomy* (ANAT3411). A number of other courses offered by anatomy compliment these gross anatomy offerings, and students with an interest in anatomy are strongly urged to undertake them: *Histology: Basic and Systematic* (ANAT2241) and *Embryology: Early and Systematic Development* (ANAT2341). Moreover, those students with an interest in microanatomy and

development will find the Level III courses *Microscopy in Research* (ANAT3212) and *Cell Biology* (ANAT3231) of interest. More generally, anatomy courses compliment the subjects offered by other areas within the School of Medical Science (i.e. Physiology, Pharmacology and Pathology) as well as courses taught in biological and biomolecular science, genetics, psychology, vision and food science, microbiology, immunology and engineering.

Teaching rationale

While in many ways this course is quite conventional, especially in terms of teaching strategies, students are strongly encouraged to engage with the ideas and materials covered. The role of the teacher (lecturer/tutor) is to impart knowledge, but also to help students navigate their way through the vast subject that is anatomy. Students should feel free to question and think critically, even about basic knowledge covered; things that might be considered unwavering 'facts'. With this in mind, students are strongly encouraged, and will be supported to be, enquiring; to ask questions, make pertinent observations, and to share experiences and knowledge with the lecturer/tutors and classmates. The philosophy of the course is also fundamentally about helping students to develop an enthusiasm for learning, especially about their own body and biology. This course also aims to exploit the teaching-research nexus, by feeding research findings and developments, as well as knowledge and skills of the teachers, into teaching and learning.

Teaching strategies

Teaching and learning are a mixture of traditional style lectures and laboratories, as well as videos, where relevant. This course comprises two x one hour lectures, and one x three hour laboratory, per week (total of five hours per week).

Lectures (all in Biomedical Theatre A)	Laboratory (all in room 101 Wallace Wurth Bldg)
Tuesday 2:00-4:00pm Weeks 1-7,9-12*	Wednesday 11:00am-2:00pm Weeks 1-7,9-12* OR Wednesday 2:00pm-5:00pm Weeks 1-7,9-12*

* Note that in weeks 8 and 13 there are no lectures and that in weeks 7 and 13 there are revision sessions. The week 7 revision sessions are on Thursday 11 September (outside the normal class timetable). The Week 13 revision sessions are on Tuesday before and during the normal Tuesday lecture times (see timetable below for details). Spot test 1 and 2 are during the normal Wednesday practical times of Weeks 8 and 13 (also see course timetable below).

Ethical behaviour and human remains

In this course, you will be required to study human anatomical (prosected = professionally dissected) specimens. Each year, people donate their bodies to UNSW so that you and your colleagues can learn about the human body directly from their remains. These are precious materials provided through the extraordinary generosity of the public (our donors and their families). This is a special privilege afforded very few people. By law, responsibility to the donor and their family members, and as a matter of good ethical practice you must treat all human remains with great respect and care.

Anatomical terms

One of the largest challenges for new students in anatomy is learning anatomical terms. In many ways the process is like learning a new language. All scientific disciplines have a set of terms and across the whole of science they are derived mostly from Latin and Ancient Greek words. Why Latin and Ancient Greek? Latin, in particular, is a 'dead' language, meaning that no one alive today uses it as the 'mother' tongue. Thus, it is not subject to fashions and constant change, like most living languages, especially English. Moreover, the spelling of Latin and Ancient Greek words has been agreed to for a long time.

In Australia and other English speaking countries, anatomical terms are Anglicised (translated to English). This means that in many cases the terms we teach are the English equivalent of the Latin or Greek word (e.g. Latin = *Corpus ossis ilii*; English = Body of the ilium). There are, however, still plenty of Latin and Greek terms used. Their pronunciation, however, is an entirely different matter. It varies greatly across English speaking countries; even at UNSW you will find lecturers employing different pronunciations, partly as a result of where they learned their anatomy! What matters is that we all know which structure we are referring to when we use a particular term; there are no points for correct pronunciation as most of the variants are equally correct!

An international organisation called the *Federative Committee on Anatomical Terminology* with representatives from many countries has published the standard (agreed) set of anatomical terms that anatomists follow. It is called *Terminologia Anatomica* and the last edition was published in 1998. Most internationally oriented textbooks (such as *Gray's Anatomy*) apply *Terminologia Anatomica*. In this course, we strive also to use this standard set of anatomical terms as much as possible as we believe that it represents best international practise as well, as making it easier for you to learn.

The terms that you need to know in laboratory classes are given in **bold**. You should, however, endeavour to understand all of the information given in laboratories in order to do well in the course.

Assessment

1. Spot Test 1	30%
2. Spot Test 2	20%
3. Written Exam	50%

1. Spot tests

These tests are held in room 101 the Anatomy Dissection Laboratory and aim at assessing the student's knowledge and skills acquired during the laboratory classes. *Format*: students will have approximately 2 minutes each at 12 (spot test 1) and 8 (spot test 2) stations (with 2 minute rest spots in between) to name structures which have been labelled on specimens and/or models. At all stations there will also be theory questions relating to the labelled structures. Tests usually run no more than 1 hour. This assessment contributes to the development of graduate attributes 1-4 (see above).

- Spot Test No.1: Covers the practical content covered in Weeks 1-7.
To be held Week 8 during the normal Wednesday Practical times.
- Spot Test No.2: Covers the practical content covered in Weeks 9-12.
To be held Week 13 during the normal Wednesday Practical times.

2. Written tests

A single 2 hour written exam will be held during the formal examination period. The aim of this exam is to assess the student's knowledge of the course's lecture and practical class content as well as their ability to make connections between ideas and problem solve. The written exam will usually comprise 50 multiple choice questions, 20 short answer questions, as well as 3 to 4 short essay questions. Some of the essay questions may require the adding of labels and text to tables, graphs and/or pictures whilst others may require long text only answers.

Failure to sit a test

Failure to sit a test without lodgement of an application for consideration with Student Central will lead to automatic failure of the test. A student may be required to sit a separate test paper or written assignment in place of a missed exam.

Resources for students

Recommended Text, Atlas & Web Resource:

Marieb EN, Wilhelm PB & Mallat J (2014). *Human Anatomy, 7th ed. (International Edition)*, Pearson Benjamin Cummings.

Hutchinson M, Mallat J, Marieb EN, Wilhelm PB (2007). *A Brief Atlas of the Human Body, 2nd ed.*, Pearson Benjamin Cummings.

Anatomy Practice Lab 2, Pearson Benjamin Cummings. Available for purchase through:
http://wps.aw.com/wps/media/access/Pearson_Default/8619/8826019/login.html

Other Texts:

Other books which may be used instead of or in addition to the recommended text:

- Tortora GJ & Nielsen MT (2012). *Principles of Human Anatomy, 12th ed.*, Wiley.
- Snell R (2007). *Clinical Anatomy by Systems*. Lippincott, Williams and Wilkins.
- Drake R, Vogl AW & Mitchell AWM (2010). *Gray's Anatomy for Students, 2nd ed.*, Churchill Livingstone.
- Moore K, Dalley A & Agur AMR (2010). *Clinically Oriented Anatomy, 6th ed.*, Lippincott, Williams and Wilkins.

Other Atlases:

Other atlases which may be used instead of or in addition to the recommended atlas:

- Nielsen MT & Miller S (2011). *Atlas of Human Anatomy*, Wiley.
- Rohen J, Yokochi C & Lütjen-Drecoll E (2010). *Color Atlas of Anatomy: A Photographic Study of the Human Body, 7th ed.*, Lippincott, Williams and Wilkins.

Lecture recordings:

Digital recording of all lectures will be made via the University's *Echo* system. PDF files of the lecture presentations will also be available after the lecture has been given (for the student to review whilst viewing to the Echo recordings). Note that hardcopies of the lecture slides and/or notes will not be provided. Lectures and accompanying materials will be made available on the *Moodle* course homepage.

What is plagiarism?

Plagiarism is the presentation of the thoughts or work of another as one's own.

Examples include:

- direct duplication of the thoughts or work of another, including by copying material, ideas or concepts from a book, article, report or other written document (whether published or unpublished), composition, artwork, design, drawing, circuitry, computer program or software, web site, Internet, other electronic resource, or another person's assignment without appropriate acknowledgement;
- paraphrasing another person's work with very minor changes keeping the meaning, form and/or progression of ideas of the original;
- piecing together sections of the work of others into a new whole;
- presenting an assessment item as independent work when it has been produced in whole or part in collusion with other people, for example, another student or a tutor; and
- claiming credit for a proportion a work contributed to a group assessment item that is greater than that actually contributed.

For the purposes of this policy, submitting an assessment item that has already been submitted for academic credit elsewhere may be considered plagiarism. Knowingly permitting your work to be copied by another student may also be considered to be plagiarism. Note that an assessment item produced in oral, not written, form, or involving live presentation, may similarly contain plagiarised material. The inclusion of the thoughts or work of another with attribution appropriate to the academic discipline does not amount to plagiarism.

The Learning Centre website is main repository for resources for staff and students on plagiarism and academic honesty. These resources can be located via:

www.lc.unsw.edu.au/plagiarism

The Learning Centre also provides substantial educational written materials, workshops, and tutorials to aid students, for example, in:

- correct referencing practices;
- paraphrasing, summarising, essay writing, and time management;
- appropriate use of, and attribution for, a range of materials including text, images, formulae and concepts.

Individual assistance is available on request from The Learning Centre.

Students are also reminded that careful time management is an important part of study and one of the identified causes of plagiarism is poor time management. Students should allow sufficient time for research, drafting, and the proper referencing of sources in preparing all assessment items.

Grievance procedures

If you have a problem or grievance with the course, you should first attempt to resolve it with the course authority. If you feel that your grievance has not been resolved in this way, it should be directed to the Departmental Grievance Officer, currently Dr Priti Pandey, Room G5.

Continual course improvement

In this course evaluative feedback on this course is gathered at the completion of the course, using among other means, UNSW's Course and Teaching Evaluation and Improvement (CATEI) Process. Student feedback is taken seriously, and continual improvements are made to the course based in part on such feedback. Based on feedback from 2008-2011 the amount of material covered in some practical classes has been modified and the order in which some topics are presented has been changed.

Practical Class Attendance Requirement

There is an 80% attendance requirement for the 11 practical classes of this course and a role will be taken by your tutor at any time during each practical class (please note that the revision classes are not compulsory and are NOT included in this requirement). The physical study of anatomical specimens, models and x-rays is an essential component of Introductory Anatomy. If you do not attend the practical classes and study these items then you have not satisfactorily completed this requirement. Any missed class (for either health and/or any other reason) will be counted as an absence. If you are absent for 3 or more of the 11 practical classes then you will be given an absent fail for the course. An application for special consideration should be lodged with the student centre for any class which is missed for health reasons.

Guidelines on extra-curricular activities affecting attendance

1. Background to Guidelines

This policy relates to the following extra-curricular activities:

1. Employment.
2. Voluntary work.
3. Sport, music or other recreational activities.
4. Student-related activities e.g. conferences and courses.
5. Academic activities e.g. conferences and courses.

2. Guidelines

1. Failure to meet attendance requirements because of extra-curricular activities will not be accepted unless prior approval is obtained.
2. Failure to meet assessment requirements (e.g. failing to submit assignment by deadline, failing to attend an examination) because of extra-curricular activities will not be accepted unless prior approval is obtained.
3. Under no circumstances will external work requirements be accepted for non-attendance. The School understands the need for many students to work part-time but this must be arranged so as it does not affect attendance.
4. Approval for non-attendance will be considered for the following activities:
 - A single, significant activity related to voluntary work. Note that regular voluntary work will not be accepted for recurrent absences.
 - A single, significant activity related to sport, music or other recreational activity being undertaken at an elite or semi-professional level. Note that regular sporting or other recreational activities will not be accepted for recurrent absences.
 - Attendance at student-related conferences/courses organised by student organisations or health professional groups and national or international education meetings.
 - Attendance at conference for academic purposes including presenting papers from Honours projects.
5. Approval to attend an extra-curricular activity must be obtained before the event and will not be taken into consideration retrospectively if a student has failed to meet attendance or assessment requirements.
6. Approval to attend an extra-curricular activity does not exempt a student from meeting attendance or assessment requirements. Approval will depend on:
 - The overall impact on attendance and whether class or other teaching activities can be made up at an alternative time to ensure that the course requirements have been met. Students requesting long periods of absence will be required to take leave and attempt the course later.
 - The nature of the assessment and whether an alternative mechanism is available to meet the assessment requirement. This may include extension of a deadline for submission of an assignment or sitting an examination at a later time. As a rule, additional examinations cannot be held and a student would be required to sit a missed examination when supplementary or later rounds are being conducted. This may delay a student's progress.

Approval will not be granted if alternative arrangements for meeting attendance or assessment requirements cannot be made.

7. Approval will also depend on the student's academic performance and will not be granted if disruption to the student's progress would be considered disadvantageous.

3. Obtaining permission to attend extra-curricular activities

1. Approval to be absent from a course for one week or more, or when the 80% attendance rule may be contravened, must be obtained from the Course Convenor. Students must contact the Course Convenor as early as possible to ensure that alternative arrangements can be made. Late requests are unlikely to be approved, as alternate arrangements cannot be made without sufficient notice.
2. If temporary absence from a course is approved, the student must inform the School of Medical Sciences student administrator (Carmen Robinson).

The School of Medical Sciences will not consider financial consequences to students (e.g. loss of registration fees for conference, loss of grant) if students have already made arrangements to attend extra-curricular activities without approval.

Health & Safety Rules for Students in the Dissecting Room

There are some rules that are enforced for the safety of the staff and students, while others are concerned with the need for care and respect of the prosection material.

General courtesy

- Students are required to attend **each lecture and the assigned tutorial/laboratory class** unless given special permission. Provision of an appropriate medical certificate to the course authority will be required for any Special Consideration.
- You may **enter** and **view** specimens in the Dissecting Room 101 **only** in the presence of your tutor and/or during your designated tutorial/laboratory class hours. You are **not permitted** to take visitors into the Dissection Room.

Health and Safety Rules

A detailed risk assessment for student activities in the Dissecting Room is located on the notice board at the front entrance (near 1st floor lifts).

When in the Dissecting Room, you are required to:

- **always put on your laboratory coat** when you enter the lab. If you have forgotten to bring your lab coat, purchase a disposable coat from the ground floor in WW building or the Union shops on campus. Lab coats must not be worn in the hall or anywhere outside the laboratories.
- **wear covered shoes with enclosed heels**, never thongs or sandals.
- **wear latex or vinyl gloves** when touching wet specimens (gloves are available from the Union Shop near CLB theatres).
- **never eat or drink.**
- **never put anything in your mouth.** For example, pens or pencils that you may have picked up from the table.
- **avoid inhaling** preservative solutions for prolonged periods. If you feel in need of fresh air, ask permission to leave the laboratory for a few minutes.
- **report all accidents** or incidents immediately to a staff member for assessment without exception. Injuries involving sharps or needle-stick will require a blood test as soon as possible.

At the end of your laboratory class:

- **cover wet specimens** with the towels provided. Make sure that towels do not hang over the edge of the table, because this allows fluid to drip onto the floor. Fluids on the floor are a major safety hazard and should be reported to staff immediately.
- **replace stools** under the tables in your cubicle.
- **remove your gloves** and dispose in the biowaste bins provided.
- **wash your hands** and instruments thoroughly with the soap provided and dry your hands with the paper towel.
- **remove your laboratory coat** when you leave the dissecting room.

Preservative solution

There are 3 main chemicals used as preservation fluids in the Dissecting Room:

phenoxyethanol (2% in solution);
methylated spirits (10%) and
formalin (5%)

The safety data sheets (SDSs) for these chemicals are located by the lab First Aid Kit and also on the notice board outside the lab. Women of reproductive years, and especially those who know they are pregnant, should note that all of these are suspected human reproductive and

developmental toxins and therefore may pose a hazard to the unborn child. In addition, formalin (**formaldehyde** solution) is a human carcinogen. Avoid these chemicals coming into contact with your eyes and skin and they should not be ingested.

Most anatomy specimens are stored in 2% phenoxyethanol, which is classified as relatively non-toxic. You should always wear gloves when handling specimens and must avoid ingestion of this chemical and contact with your skin or eyes. Formaldehyde is reported to cause allergic skin and respiratory effects. The potential for adverse health effects, however, is markedly reduced at the concentrations used for embalming and storage of specimens in the Dissecting Room, i.e., the “formalin” solution is less than 5% of a 37% solution of formaldehyde. The specimens provided for classes are without any formalin and a combination of air extraction and conditioning continuously changes the air in the Dissecting Room.

First Aid

If assistance is needed during office hours you may approach **Room 101** staff for **First Aid**. **All incidents must be reported**. The First Aid Kit is located on the left wall near the Dissecting Room entrance door. A second First Aid Kit in the east wing on the ledge opposite cubicle E4.

Emergency evacuation

In the case of a fire or other emergency the evacuation alarm will sound. When it sounds for the first time this indicates that everyone should get prepared in case it is necessary to evacuate. When it sounds for the second time, an announcement will be made over the speaker system - **follow these instructions**. Staff will be on hand to supervise any evacuation and the emergency exit is at the south end of the lab, do **not use the lifts**. The evacuation assembly area is the landscaped space immediately to the east of the Chancellery and adjacent to the Clancy Auditorium. **Do not assemble anywhere else** and do not leave this area until instructed.

Additional Safety Information

If additional safety information is required you can ask the course convenor or the Anatomy Dissection Laboratory Manager (Mr Vincent Strack). The latest safety information is always available from the SOMS HS Webpage.

<http://medicalsciences.med.unsw.edu.au/SOMSWeb.nsf/page/Health+and+Safety>

Care and respect of prosected material

You are learning from human material prepared from people who have generously donated their bodies for the benefit of science. Skilled staff members have dissected the specimens to allow you, the student, to see anatomical structures in fine detail. Apart from caring for the specimens, it is important for all students learning Anatomy to have and show **utmost respect** for the specimens at all times, in the Dissecting Room, Room 101, and in the Anatomy Museum Room 105. **Great care** should always be exercised when handling specimens, in order to preserve their delicate structure.

Some specific points:

- **Always use only blunt forceps** to handle specimens and **probes** to point to structures, i.e. **never pull** at any parts of the specimen.
- It is **illegal** for any anatomical material to be removed from the premises of the Department of Anatomy for any purpose whatsoever (except of course, for the funeral). All anatomy specimens are micro-chipped for identification and record keeping.
- Photography and video recording are **not permitted** in the Dissecting Room 101, or the Anatomy Museum 105.

• Ken Ashwell 30th January 2014

Due for review: 30th January 2015

Medicine Teaching Laboratory
Student Risk Assessment



Gross Anatomy Practical Classes for Medical and Science Students

DOC:PHSL-SRA-S&H-01rev1.1

Hazards	Risks	Controls
Physical Cold temperature (16°C) Sharp bone/plastic Biological Fungi, bacteria (tetanus), hepatitis B and C Chemical Formaldehyde Methanol 2-phenoxyethanol	Cold Penetrating wound of foot Infection Corrosive/Flammable Irritant/toxic Irritant	<ul style="list-style-type: none"> Wear laboratory coat over appropriate warm clothing Wear enclosed shoes with full coverage of the dorsum of the foot Have appropriate immunisation Do not eat, drink or smoke in the Dissecting Room Do not place anything (e.g. pens, pencils) into your mouth Use disposable gloves when handling wet specimens and do not cross-contaminate models or bones with wet specimens Always wash hands with liquid soap and dry thoroughly with disposable paper towel before leaving Low concentrations of chemicals used Chemicals used in well ventilated area Safety Data Sheets for chemicals available in the laboratory

Personal Protective Equipment required



Closed in Footwear



Lab. Coat



Gloves

Emergency Procedures

In the event of an alarm sounding, stop the practical class and wait for confirmation to evacuate from demonstrators. Then wash your hands and pack up your bags. Follow the instructions of the demonstrators regarding exits and assembly points.

Clean up and waste disposal

- Cover wet specimens with the towels provided. Make sure that towels do not hang over the edge of the table, because this allows fluid to drip onto the floor. Fluids on the floor are a major safety hazard and should be reported to staff immediately.
- Replace stools under the tables in your cubicle.
- Remove your gloves and dispose in the biowaste bins provided.
- Wash your hands and instruments thoroughly with the soap provided and dry your hands with the paper towel.
- Remove your laboratory coat when you leave the dissecting room.

Ethics Approval

This type of practical has been previously considered and approved by the UNSW Human Research Ethics Advisory Panel (HREC09372).

Declaration

I have read and understand the safety requirements for this practical class and I will observe these requirements.

Signature: Date:
 Student number:

Course Schedule: Semester 2, 2014

Week	Date	Lectures (Tuesday 2-4pm)	Date	Practicals (Wednesday 11am-2pm or 2-5pm)
1	29 Jul	What is Anatomy? General Anatomy Skeletal System 1	30 Jul	General Anatomy & Skeletal System 1
2	5 Aug	Skeletal System 2 Articular System	6 Aug	Skeletal System 2 & Articular System
3	12 Aug	Muscular System 1 - Muscles of Axial Skeleton Muscular System 2 - Muscles of Upper Limb	13 Aug	Muscular System 1
4	19 Aug	Muscular System 3 - Muscles of Lower Limb Nervous System 1 - Brain	20 Aug	Muscular System 2 & Brain
5	26 Aug	Nervous System 2 - Spinal Cord Nervous System 3 - Spinal Nerves	27 Aug	Spinal Cord & Spinal Nerves
6	2 Sept	Nervous System 4 - Cranial Nerves Nervous System 5 - Autonomic Nervous System	3 Sept	Cranial Nerves & Autonomic Nervous System
7	9 Sept	Nervous System 6 - Eye Nervous System 7 - Ear	10 Sept	Eye & Ear
8	16 Sept	Revision of Weeks 1-7 Practical	11 Sept	Thursday 11 Sept. 11am-2pm or 2-5pm
9	23 Sept	No Lectures Cardiovascular System 1 Cardiovascular System 2	17 Sept	Spot Test No.1 covering Weeks 1-7 Practical (Wednesday 17 Sept. 1-2pm or 2-3pm - No Labs)
10	7 Oct	<i>Mid-Semester Break (29 Sept. - 3 Oct.)</i> Respiratory System 1 Respiratory System 2	24 Sept	Cardiovascular System
11	14 Oct	Digestive System 1 Digestive System 2	8 Oct	Respiratory System
12	21 Oct	Urinary System Reproductive Systems	15 Oct	Digestive System
13	28 Oct	Revision of Weeks 9-12 Practical No Lectures	22 Oct	Urinary & Reproductive Systems
			29 Oct	Spot Test No.2 covering Weeks 9-12 Practical (Wednesday 29 Oct. 1-2pm or 2-3pm - No Labs)

Week 1: General Anatomy, General Skeletal System & Axial Bones

Learning Objectives

1. Understand the appropriate behaviours and procedures for the use of human remains in the anatomical sciences at UNSW (legislative and ethical).
2. Know how bodies are stored, prepared and dissected at UNSW, and by whom and where.
3. Know and understand the anatomical position and understand and be able to use the major planes of the human body in your study.
4. Be familiar with and understand major terms of relationship and comparison in anatomy and know the terms of laterality.
5. Be familiar with the major tissue types seen in gross anatomy and know important examples of these tissues.
6. To briefly describe the chief components and main functions of the major body systems (musculoskeletal, cardiovascular, nervous, respiratory, gastrointestinal and urogenital systems).
7. Know the major functions of the skeleton, understand some major features of bones and be familiar with the bone types based on shape.
8. Understand the parts of a typical long bone.
9. Be familiar with major bones and features of the cranium.
10. Know the major features of a typical vertebra and the general differences between vertebral regions.
11. Understand the difference between 'true', 'false' and 'floating' ribs.

Learning Activities

Rules for Students in the Dissecting Room

1. With your tutor, review the rules for students in the dissecting room (page 9) and discuss the ethical considerations associated with the use of anatomical material. Read and sign the declaration on page 11 acknowledging the safety requirements for attending the practical classes of this course.

Tissue types

In accordance with their general appearance and function, the tissues of the body are often classified into four major groups. In this laboratory, you are required to observe examples of different tissue types and discuss and learn their different material properties and functions.

2. **Epithelia:**
usually sheets of tissue covering other tissues, or lining cavities that communicate with the exterior. A good example is the external covering of the body – the **skin** or **integumentary system** – and another is the tissue that provides a lining for the major cavities of the body, surrounds the heart and abdominal organs (viscera) – **mesothelium**. On wet specimens, observe to following examples of epithelium:
 - a. **Skin:** noting hard superficial layer or **epidermis**.
 - b. **Mesothelium** lining the **abdominal** (peritoneal) **cavity**.
3. **Connective tissue:**
involved in the connection, support or protection of other tissues and organs. The principal types are **loose connective tissue**, **dense connective tissue**, **blood**, **bone** and **cartilage**. On wet specimens, observe to following examples of connective tissue:
 - a. Subcutaneous tissue or **superficial fascia**, including subcutaneous **adipose** (fat) tissue. This is an example of loose connective tissue.
 - b. The **patella ligament** is associated with the quadriceps femoris muscle and knee cap (**patella**). This is an example of dense connective tissue.
 - c. **Bone:** cells and fibres exist within a solid matrix. Observe several bones on the skeleton.

d. **Cartilage:** Cells exist in a semisolid matrix - covers joint (articular) surfaces of bones. Also found in the respiratory pathway and outer ear.

4. **Nervous tissue:**

specialised tissue for the conduction of nerve impulses to and away from the **central nervous system** (or **CNS**). On wet specimens, observe to following examples of nerve tissue:

a. The **spinal cord** (part of the CNS).

b. The **sciatic nerve:** the major nerve of the lower limb (part of the peripheral nervous system or **PNS**).

5. **Muscle tissue:**

three types found in the body:

a. **Smooth muscle:** found within the walls of body organs and blood vessels.

b. **Cardiac muscle:** confined to the heart and bases of the great vessels.

c. **Skeletal** (or voluntary) **muscle:** the greater mass of muscle in the body. Attaching directly or indirectly (via tendons) to bones, cartilages, ligaments, fascia, organs and mucous membranes. Find examples on the wet specimens.

Standard reference position and anatomical terminology

Listen to an explanation by your tutor of the anatomical position, planes and terminology:

6. **The Anatomical Position:**

provides the basic reference or spatial framework for describing the body, the relationships of its structures, and movements of the body. In this position, the person is standing, the feet are parallel, eyes straight forward, and the arms lie to the side, palms facing forward with fingers pointing straight down (refer to your own body and the articulated skeleton in your cubicle).

7. **Body Planes:**

Be familiar with and able to use the following body planes when studying human remains (refer to your own body and the articulated skeleton in your cubicle):

Sagittal (median) plane.

Coronal plane.

Horizontal (transverse) plane.

8. **Terms of Relationship and Comparison:**

Know, understand and be able to correctly use the following terms (refer to your own body and the articulated skeleton in your cubicle):

Superficial (near or towards the external body/surface) and **deep** (away from the external body/surface). On a wet specimen of a lower limb, abdomen or pelvis identify structures (any) that are **superficial** (at or close to the external surface), such as the epidermis of the skin, and structures that are **deep**, such as the muscles or bones of the thigh or leg.

Superior/rostral (at or towards the top/cranium) and **inferior/caudal** (at or towards the bottom/feet). Observe on a skeleton that the cranium (skull) is superior to the thoracic cage (ribs); while the thoracic cage is superior to the pelvis. The lower limbs are inferior to the pelvis; while the pelvis is inferior to the cranium.

Anterior (or ventral) and **posterior** (or dorsal). Observe on a skeleton that the patella is the anterior part of knee joint; while the spinal column is posterior to the sternum.

Medial (at or towards the midline or median plane of the body) and **lateral** (away from the midline or median plane of the body).

Proximal (nearer to the trunk) and **distal** (away from the trunk).

Select a large bone such as the humerus or femur and note the superior, inferior, proximal and distal parts of the bone. Are there instances where two anatomical terms (e.g. superior and proximal) describe the same part of the bone? Which are the anterior, posterior, medial and lateral surfaces of the shaft?

Major Body Systems

9. On the torso models provided identify the main components (listed below) of each of the major body systems. In your own time complete the table below:

- Heart, veins, arteries (cardiovascular system)
- Larynx, trachea bronchi & lungs (respiratory system)
- Oesophagus, stomach, intestines, liver (digestive system)
- Kidneys, urinary bladder (urinary system)
- Prostate, testes, uterus, ovaries (reproductive systems)

SYSTEM	MAJOR COMPONENTS	MAIN FUNCTIONS
Skeletal		
Articular		
Muscular		
Nervous		
Cardiovascular		
Respiratory		
Digestive		
Urinary		
Reproductive		

The Skeleton System

10. The human adult skeleton comprises about 206 bones. The main functions of the skeletal system are to give the body its shape/architecture, house and protect organs, provide surfaces for muscles to attach and to facilitate movement. In addition bones are responsible for the production of red blood cells (within the bone marrow) and storage of minerals.

Skeleton System: Bone Types

11. The bones of the human skeleton can be classified according to their general shape. Learn the shapes and their general characteristics; study the examples given:
- a. **Long bones:** Found in the limbs; length is greater than breadth; have a cylindrical shaft and a swelling at each end.
Examples: Humerus, femur, metacarpals, metatarsals and phalanges.
 - b. **Short bones:** Found in the wrist and ankle; roughly cuboidal in shape. **Sesamoid bones** are also a type of short bone but are nodules of bone found in certain tendons.
Examples: Bones of the carpus (wrist), tarsus (ankle) and Patella (knee cap).
 - c. **Flat bones:** Found mostly in the vault of the cranium (skull); flat and thin bones.
Examples: Frontal, parietal and occipital bones, ribs.

- d. **Irregular bones:** Those not classified as long, short or flat bones.
Examples: Vertebrae and bones of the pelvis.

Skeleton System: General Features of Bones

12. Bones are complex organs that provide structure for the body, areas for the attachments of muscles and other structures. Learn the following surface markings and observe some examples:
- **Foramen:** passage through a bone; e.g. foramen magnum.
 - **Meatus:** path or passage way to an organ; e.g. the external acoustic meatus.
 - **Fossa:** hollowed or depressed area; e.g. middle cranial fossa.
 - **Process:** a projection; e.g. the spinous process of a vertebra.
 - **Tuberosity:** large flat convexity; e.g. the ischial tuberosity of the pelvis
 - **Tubercle:** small raised eminence; e.g. the greater tubercle of the humerus.
 - **Trochanter:** large blunt elevation; e.g. the greater trochanter of the femur.
 - **Malleolus:** rounded process; e.g. medial malleolus of the tibia.
 - **Condyle:** rounded articular area; e.g. lateral condyle of the femur.

Skeleton System: Features of a Long Bone

13. Examine a typical long bone such as the humerus or femur and observe the:
- a. **Diaphysis:** the **shaft** of the long bone, formed primarily by compact bone. It is cylindrical, with a marrow cavity in its centre.
 - b. **Epiphyses:** the swellings at each end of the bone, formed by spongy (cancellous) bone covered by compact bone.
 - c. **Articular surfaces:** those parts of the ends (proximal and distal) that participate in a joint. They are covered by articular cartilage.
 - d. **Periosteum:** The non-articular surfaces of living bones are covered by a membrane called the **periosteum**, which is essential for bone repair, is the site of attachment of tendons and ligaments and contains sensory nerves.

Skeleton System: Functional Regions of the Skeleton

14. The bones of the skeleton can be broadly divided into two functional groups, the axial skeleton (trunk and head) and the appendicular skeleton (limbs):
- a. **Axial skeleton** (or bones of the axial skeleton)
Axis of the body, provides posture and support for the body, provides protection for the vital organs, and attachment for major muscles of limb movement.
Identify the following bones:
 - Skull - cranium, face, mandible
 - Vertebral column - made up of 7 cervical vertebrae, 12 thoracic vertebrae, 5 lumbar vertebrae, and the sacrum and coccyx.
 - Ribs - 12 pairs
 - Sternum
 - b. **Appendicular skeleton** (or bones of the appendicular skeleton)
Girdles for attachment of the limbs to the body axis, as well as bones of the limbs and their joints; facilitates movement of the body.
Identify the following bones
 - Upper limb - clavicle scapula, humerus, radius and ulna.
 - Lower limb - hip bone, femur, patella (knee cap), tibia and fibula.

Axial Skeleton: The Skull

15. Examine the bones of the skull. Note that these bones are divided into two groups: bones of the **cranium** and bones of the **facial skeleton**.

Identify the following bones and features of the skull:

Cranial Exterior:

- a. **Frontal bone** (1)
- f. **Foramen magnum**

- b. **Parietal bones** (paired)
- c. **Temporal bones** (paired)
- d. **Occipital bone** (1)
- e. **Sphenoid bone**(1)
- g. **Occipital condyles**
- h. **External acoustic meatus**
- i. **Mastoid process**

Cranial Interior:

- a. **Anterior cranial fossa** - formed primarily by the frontal bone
- b. **Middle cranial fossa** - formed by sphenoid and temporal bones
- c. **Posterior cranial fossa** - formed by occipital and temporal bones.
- d. **Hypophyseal (pituitary) fossa** - within the sphenoid bone
- e. **Petrous part of the temporal bone** - boundary between (b) and (c)

Facial skeleton:

- a. **Zygomatic (cheek) bones** (paired)
- b. **Maxillae** (paired)
- c. **Nasal bones** (paired)
- d. **Mandible** (1) - body, angle and ramus

Axial Skeleton: The Vertebral Column

16. The vertebral column is the central pillar of the body and provides support for the cranium, shoulder girdle, upper limbs and thoracic cage, and transmits weight to the lower limb. Within its cavity – the **vertebral canal** – the spinal cord extends from the brain and gives rise to the peripheral nerves. The vertebral column typically comprises 33 vertebrae. Examine an articulated vertebral column and isolated vertebrae and identify the following components and typical features:

Vertebral column

- a. **Cervical** (neck) **vertebrae** (7)
- b. **Thoracic** (thorax) **vertebrae** (12)
- c. **Lumbar** (abdomen) **vertebrae** (5)
- d. **Sacral vertebrae**
(5 fused to form the sacrum)
- e. **Coccygeal**
(lower 3-4 fused to form the coccyx)
- f. **Intervertebral discs**
(fibrocartilaginous joints, see week 2)
- g. **Intervertebral foramina**
(between vertebrae, formed by notches)

Isolated vertebra

- a. **Vertebral body**
- b. **Vertebral foramen (canal)**
- c. **Pedicle**
- d. **Lamina**
- e. **Spinous process**
- f. **Transverse processes**
- g. **Superior articular facet**
- h. **Inferior articular facet**
- i. **Superior vertebral notch**
- j. **Inferior vertebral notch**

Axial Skeleton: The Thoracic Cage

17. Using an articulated skeleton, observe that the thoracic cage is formed by the thoracic vertebrae, **sternum** (comprised of the **manubrium**, **sternal body** & **xiphoid process**), and 12 pairs of ribs (numbered 1-12 from above downward).
- a. Ribs 1-7 are called the **true ribs** because they attach directly to the sternum via their own costal cartilage.
 - b. Ribs 8-10 are called the **false ribs** because they attach indirectly to the sternum via shared costal cartilage.
 - c. Ribs 11-12 are called the **floating ribs** because they do not attach to the sternum.

Materials:

- Superficial abdominal specimen with skin with subcutaneous tissue, mesothelium and gastrointestinal tract, lower limb specimen with muscles, patella ligament and sciatic nerve, deep dissected knee joint and isolated spinal cord and heart specimens.
- Torso model, full articulated skeleton, skull, vertebrae, ribs, sternum, vertebrae, humerus, femur, wrist and hand and patella bones.

Week 2: Appendicular Bones & The Articular System

Learning Objectives

1. Know the major features of the bones of the upper limb and pectoral girdle.
2. Know the major features of the bones of the lower limb and pelvic girdle.
3. Understand the major types of joints as classified according to their structure.
4. Know some examples of these joints in the human body and the movements they allow and prevent.
5. Understand the major characteristics of synovial joints.
6. Be familiar with the functions of ligaments.
7. Describe the major features of the knee, shoulder, hip and ankle joints and the factors affecting their stability.
8. Be familiar with the structure and function of intervertebral discs.

Learning Activities

Appendicular Skeleton

1. The appendicular skeleton consists of the following bony elements:
 - a. Bones of the shoulder girdle: **clavicle** and **scapula**
 - b. Bones of the upper limbs: **humerus**, **radius**, **ulna**, **carpals**, **metacarpals** and **phalanges**
 - c. Bones of the pelvic girdle: the **hip bones (ilium, ischium and pubis)**
 - d. Bones of the lower limbs: **femur**, **tibia**, **fibula**, **tarsals**, **metatarsals** and **phalanges**

Appendicular Skeleton: Shoulder Girdle

2. The **clavicle** is a long and slender bone that lies horizontally across the base of the neck. Note how it articulates with both the sternum and the scapula.

The **scapula** is a flat triangular bone that lies on the posterior thoracic wall. Examine and learn the following features on a scapula:

- a. **Spine**
- b. **Acromion**
- c. **Glenoid fossa**
- d. **Coracoid process**
- e. **Supraspinous and infraspinous fossae**
- f. **Subscapular fossa**

Appendicular Skeleton: The Upper Limb

3. The **humerus** is a long bone and forms the proximal bone of the upper limb or the arm bone. Examine and learn the following features:
 - a. **Head**
 - b. **Greater tubercle**
 - c. **Lesser tubercle**
 - d. **Shaft**
 - e. **Trochlear**
 - f. **Capitulum**
 - g. **Medial and lateral epicondyles**
4. The **radius** is the lateral bone of the forearm. Examine and learn the following features:
 - a. **Head**
 - b. **Neck**
 - c. **Radial tuberosity**
 - d. **Shaft**
 - e. **Styloid process**
5. The **ulna** is the medial bone of the forearm. Examine and learn the following features:
 - a. **Olecranon process**

- b. **Trochlear notch**
 - c. **Ulnar tuberosity**
 - d. **Head**
 - e. **Styloid process**
6. The **wrist** or **carpus** comprises eight carpal bones. You do not need to learn its individual bones in this course.
7. The **metacarpals** are the bones of the hand proper (the palm). There are **five metacarpals** and they are numbered 1-5 from lateral to medial (hand in anatomical position): metacarpal 1 articulates with the thumb; metacarpal 2 with the index finger; metacarpal 3 with the middle finger; metacarpal 4 with the ring finger; and metacarpal 5 with the little finger.
8. The hand (manus) **digits** are the fingers. These digits comprise bones called **phalanges**, each one called a **phalanx**. The following pattern applies to the manual digits:
- a. Digit 1 (thumb): two phalanges: a proximal phalanx and a distal phalanx.
 - b. Digits 2-5: three phalanges: a proximal phalanx, a middle phalanx and a distal phalanx.

Appendicular Skeleton: The Pelvic Girdle

9. The **pelvis** is a basin-shaped structure comprising the three hip bones and the sacrum. Observe each of the three hip bones:
- a. **Ilium**
 - b. **Ischium**
 - c. **Pubis**

Identify the following examples of major features of the hip bones:

- a. **Iliac crest and fossa**
- b. **Anterior superior iliac spine (ASIS)**
- c. **Posterior superior iliac spine (PSIS)**
- d. **Obturator foramen**
- e. **Gluteal surface**
- f. **Ischial tuberosity and spine**
- g. **Greater sciatic notch**
- h. **Acetabulum** – note that it is formed by fusion of the ilium, ischium and pubis and that it forms a deep socket for the hip joint (head of the femur).

Appendicular Skeleton: Lower limb

10. The **femur** (or thigh bone) is a long bone which forms the proximal bone of the lower limb. Examine and learn the following features:
- a. **Head**
 - b. **Neck**
 - c. **Greater trochanter**
 - d. **Lesser trochanter**
 - e. **Shaft**
 - f. **Linea aspera**
 - g. **Medial and lateral condyles** and **epicondyles**
11. Identify the **patella** or knee cap is a sesamoid bone that develops within the tendon of the quadriceps muscle.
12. The **tibia** is the large weight-bearing medial bone of the leg. Examine and learn the following features:
- a. **Medial and Lateral condyles**
 - b. **Tibial plateau**
 - c. **Intercondylar eminence**
 - d. **Tibial tuberosity**
 - e. **Shaft**

f. **Medial malleolus**

13. The **fibula** is the slender lateral bone of the leg. It does not participate in the knee joint but does form part of the ankle joint. Examine and learn the following features:
- Head**
 - Shaft**
 - Lateral malleolus**
14. The **ankle** or **tarsus** comprises seven tarsal bones. Identify:
- Talus**
 - Calcaneus**
- You do not need to learn the names of the other tarsal bones for this course.
15. The **metatarsals** are the bones of the foot proper. There are **five metatarsals**, numbered 1-5 from medial to lateral (opposite to hand). Note that metatarsal 1 articulates with the great toe and metatarsal 5 with the little toe.
16. The **digits** of the foot (pes) are the toes. These digits comprise bones called **phalanges** each one called a **phalanx**. The following pattern applies to the pedal digits:
- Digit 1 (great toe): two phalanges: a proximal phalanx and a distal phalanx.
 - Digits 2-5: three phalanges: a proximal phalanx, a middle phalanx and a distal phalanx.

The Articular System

17. The articular system comprises the joints and ligaments of the human body. Their main functions are to facilitate, stabilise and/or restrict movement. Joints can be classified into 3 types - **fibrous** (least mobile), **cartilaginous** and **synovial** (most mobile).

The Articular System: Fibrous Joints

18. These joints are formed by fibrous tissue passing between the adjacent bones and are said to be immobile because they permit little or no movement between the adjacent bones. Examine the joints between the flat bones of the skull and note how the adjacent bony surfaces interlock with each other. In the living these bones are joined to each other by short bands of fibrous tissue forming fibrous joints called **sutures**. On skulls locate the:
- Coronal suture** – between frontal and parietal bones.
 - Sagittal suture** – between the two parietal bones.
 - Lambdoid suture** – between parietal and occipital bones.

The Articular System: Cartilaginous Joints

19. Also termed symphyses, these joints permit a limited amount of movement to occur between the bones. The adjacent bones are united by a pad of fibrocartilage. Fibrocartilaginous joints are found in the vertebral column and the pubic symphysis. In prosected specimens, examine the fibrocartilaginous joints between the bodies of adjacent vertebrae (anterior intervertebral joints) and identify the **intervertebral disc**.

Observe the two parts of the **intervertebral disc**:

- nucleus pulposus** in the centre - It changes shape when pressure is placed upon it, enabling movement to occur between adjacent vertebrae.
- annulus fibrosus** - consists of fibres which are arranged in concentric layers and pass obliquely from one vertebra to the next, providing a strong union between them, able to resist excessive movement in most directions.

Note the intervertebral discs are wedge-shaped in the lumbar and cervical regions and contribute to the **spinal curvatures** (convex anteriorly) in these regions.

What is a slipped disc? How does it occur?

The Articular System: Synovial Joints

20. These joints are usually highly mobile connections between two or more bones. Participate in a discussion with your colleagues and tutor on the types of movements that can occur at

synovial joints. Define what is meant by the terms: flexion, extension, abduction, adduction, rotation, circumduction, supination, pronation, plantar flexion, dorsiflexion, inversion, eversion?

21. Synovial joints can be classified according to the types of movements that they allow. In an articulated skeleton and prosected specimens identify examples listed for the following types of joints:

Uniaxial joints – allow movement around one axis only

- a. Hinge – **elbow, interphalangeal joints (fingers), ankle**
- b. Pivot – **proximal radioulnar joint**

Bi-axial joints – allow movement around two axes

- a. Condylloid – **metacarpophalangeal joint**

Multiaxial joints – allow movement around many axes

- a. Ball and socket – **shoulder and hip joints**

22. Examine the plastinated and wet specimens of the **knee joint** and identify the following key characteristics, typical of a synovial joint:

- a. **Capsule** (attached to the margins of articular surfaces; encloses and protects the joint).
- b. **Synovial membrane** (lines the capsule; produces lubricant called synovial fluid).
- c. **Articular cartilage** (covering bone ends).
- d. **Medial collateral ligament** (an example of a capsular ligament)
- e. **Lateral collateral, and anterior and posterior cruciate ligaments** (examples of extracapsular or accessory ligaments).
- f. **Medial and lateral menisci** – not present in all synovial joints.
- g. Suprapatella bursa- bursae are not present in all synovial joints

What movements are limited/prevented by each of above ligaments?

What is the function of the menisci?

What is the function of bursae?

23. Examine the following synovial joints in specimens, models and radiographs:

a. **Shoulder Joint:**

Observe the **articular surfaces, glenoid labrum, capsule** and **coracoacromial arch** of the shoulder joint Other than **coracoacromial ligament**, (which is part of the coracoacromial arch) ligaments of the shoulder do not need to be learned. Note the shallowness of the glenoid cavity and its small articular area compared to that of the head of the humerus. What is the function of the coracoacromial arch and the glenoid labrum? Identify the rotator cuff muscles as a group only (their details will be covered next week) and discuss their role in stabilising (preventing dislocation) of the joint.

Observe X-rays of shoulder dislocation and note the position of the head of the humerus.

b. **Hip Joint**

Observe the articular surfaces (acetabulum and head of femur), capsule and ligaments of the hip joint and compare them with those of the shoulder joint). Why is the hip joint so much more stable than the shoulder joint?

c. **Ankle Joint**

Observe the articular surfaces (tibia including **medial malleolus; lateral malleolus; talus**), capsule and collateral (**deltoid and lateral**) **ligaments** of the ankle joint. What movements occur at this joint? What is the function of the deltoid and lateral ligaments? What is an ankle sprain and how does this usually occur?

Materials:

- Vertebral columns and disarticulated vertebrae, bones of the shoulder and hip girdles, disarticulated hip bones, bones of the upper and lower limbs.
- Models of the shoulder, elbow, wrist, hand, hip, knee and ankle joints with ligaments
- Dissections of the vertebral, shoulder and knee joints.

Week 3: General Muscular System, Axial & Upper Limb Muscles

Learning Objectives

1. Know the major components of skeletal muscles and understand how they attach to bone.
2. Understand the major types of skeletal muscle with respect to their architecture/shape.
3. Know the principal ways in which muscles work (i.e. prime mover, antagonist, fixator and synergist).
4. Understand in general terms how skeletal muscles are named.
5. Be familiar with the muscles of mastication (as a group) and muscles of facial expression (as a group), sternocleidomastoid and erector spinae muscles and understand their main actions.
6. To recognise the muscles of the anterior abdominal wall.
7. Be familiar with major groups of muscles of the upper limb.
8. Know important examples of muscles connecting the upper limb to the thoracic wall and the upper limb to the vertebral column.
9. Be familiar with important examples of muscles that connect the scapula to the humerus.
10. Understand the division of arm and forearm musculature into anterior and posterior compartments and their broad alignment with muscle function.
11. Know some major muscles of the arm and forearm.
12. Be familiar with major groups of muscles of the hand: thenar and hypothenar groups.

Learning Activities

General Anatomy of Muscles

1. Study a typical skeletal muscle: a major arm, thigh or calf muscle. Skeletal muscles comprise a **belly** (containing the muscle fibres) and one or two **tendons** which attach the muscle belly to bone.
2. Examine a bone covered in **periosteum**; a layer of connective tissue (a sheath) which covers the outer surface of a bone. The fibres of muscles pass into the periosteum and often into the outer layer of the bone in anchoring the muscle belly to bone. Most skeletal muscles have two areas where they attach to bone (the '**attachments**'): they are sometimes referred to as proximal and distal attachments, or the origin and insertion of a muscle.

Major Muscles of the Head and Neck

3. In dissections of the head and neck identify the following muscles or muscle groups.
 - a. **Muscles of the orbit**: these muscles are contained within the orbit (extraocular); arising from a tendinous ring or from the walls of the orbit and attaching to the upper eyelid or eye itself. They work together to move the upper eyelid or to move the eye in a series of complicated movements within three axes. Observe these muscles as a group only at this stage (they will be covered in more depth in week 8).
 - b. **Muscles of mastication** (as a group only): these muscles facilitate movement of the mandible to bring the maxillary and mandibular teeth into occlusion (contact) for the mechanical break-down of food. Observe them and understand how as a group (i.e. in general terms) they attach the mandible the cranium and how they might function. Specifically identify and learn the following muscle of mastication:
 - **Masseter**: extending from the angle of the mandible to the zygomatic arch, it elevates the mandible (closes the jaw). It the strongest muscle (per unit of mass) in the body!You do not need to know the names of other muscles of mastication in this course nor details of the temporomandibular joint).
 - c. **Facial muscles** (as a group only): these muscles are also called the muscles of facial expression. They are all located subcutaneously (i.e. deep to the skin). They move the skin and convey facial expressions to indicate mood, as well as opening and closing of

the eyes and mouth. Specifically identify and learn the following muscles:

- **Orbicularis oculi**: surrounds the orbital margin and extends into the eyelids - closes the eyelids.
- **Orbicularis oris**: within the lips - closes the mouth

You do not need to know the names of other muscles of facial expression.

- d. The **sternocleidomastoid** muscle is a muscle that appears as an oblique band across the side of the neck. Its origins lie on the **manubrium** of the sternum and medial **clavicle** and its insertion is on the **mastoid process** of the cranium. Its major functions are to bilaterally (left and right together) flex the neck and acting alone, to rotate the head to the opposite side.

Muscles of the Back

4. The muscles of the back are usually divided into three groups:
 - a. **Superficial muscles**, which are connected to the shoulder girdle (covered below).
 - b. **Intermediate muscles**, which are involved in movements of the thoracic cage (not covered in this course).
 - c. **Deep** (postvertebral) muscles, which are the true (proper) muscles of the back and which bring about movements of the vertebral column.
5. The postvertebral muscles are well-developed in humans owing to their upright posture. Identify the major muscle of this group, the **erector spinae muscle** – made up of massive columns of muscle tissue occupying the hollow on each side of the spine (beside the spinous processes); arising (origin) from a broad tendon that attaches to the pelvis and extends to the ribs, spinous processes of upper vertebrae, and the base of the cranium. Each side alone laterally bends the vertebral column and head; together they extend the vertebral column.

Muscles of the Anterior Abdominal Wall

6. The muscles of the anterior abdominal wall consist mostly of three broad layers (sheets) superficial to deep. They have different origins and insertions: arising from the ribs, costal cartilages, anterior pelvis or lower back fascia and inserting into ribs, anterior pelvis or the rectus sheath (see below):
 - a. **External oblique muscle**: most superficial layer; fibres run inferomedially.
 - b. **Internal oblique muscle**: intermediate layer; fibres run anteromedially.
 - c. **Transversus abdominis muscle**: deep layer; fibres run horizontally (in transverse plane).
7. Another important muscle of the anterior abdominal wall is the **rectus abdominis muscle**: its fibres run vertically and it is divided into four sections superoinferiorly by tendinous intersections. It is covered by a thick wrapping of aponeurosis called the **rectus sheath**.

Muscles of the Upper Limb: Connecting the Upper Limb to the Thoracic Wall

8. There are several muscles on the anterior surface of the thoracic cage that attach the upper limb to the body (i.e. to the cage itself). These muscles are involved in moving the upper limb as well as providing stability to the shoulder joint. Observe and know the following:
 - a. **Pectoralis major muscle**: most superficial of four muscles; originates from the sternum/ribs and clavicle and attaches to the proximal humerus: multiple actions including adduction, medial rotation and flexion of the humerus.
 - b. **Serratus anterior muscle**: the deepest of the four muscles; originates on ribs 1-8 and attaches to scapula (anterior surface of the medial border); involved in moving the scapula as well as holding it against the thoracic wall.

Muscles of the Upper Limb: Connecting the Upper Limb to the Vertebral Column

9. There are several muscles on the back that attach the upper limb to the vertebral column. These muscles are involved in moving the scapula and upper limb as well as providing stability to the shoulder joint. Observe and know the following:
- Trapezius muscle:** a large superficial diamond-shaped muscle on the superior part of the back; it originates in the midline of the vertebral column (spinous processes of vertebrae and nuchal ligament) and attaches to the scapula and clavicle: multiple actions in moving and stabilising the scapula.
 - Latissimus dorsi muscle:** a large superficial fan-shaped muscle on the inferior part of the back; originates in the thoracolumbar fascia and spinous processes of inferior vertebrae and attaches to the humerus; involved in a wide range of movements of the humerus (e.g. raises body towards arms during climbing).

Muscles of the Upper Limb: Connecting Scapula to the Humerus

10. These muscles are also called the **scapulohumeral** muscles. There are six relatively short muscles which pass from the scapula to the humerus and act on the shoulder (glenohumeral) joint. Observe and know the following:
- Deltoid muscle:** the deltoid muscle is a thick and powerful muscle that covers the shoulder, forming its rounded contour. It is divided in anterior, middle and posterior parts and each has a different function with respect to the shoulder joint (i.e. flexion, medial rotation, abduction, extension and lateral rotation). Originates on the clavicle and scapula and inserts onto the proximal humerus.
 - Teres major muscle:** principally an extensor of the arm; originates from the lateral border (inferior) of the scapula and inserts onto the proximal humerus.
 - Rotator cuff group (subscapularis, supraspinatus, infraspinatus and teres minor muscles):** their principal function is to hold the head of the humerus in position during movements of the shoulder joint: they originate from the scapula and their tendons blend with shoulder capsule before inserting onto the proximal humerus. With your colleagues deduce the action of each of these muscles working individually.

Muscles of the Upper Limb: Arm

11. The arm extends from the shoulder to the elbow. Osteologically, it contains only the humerus. Two types of movements occur between the arm and forearm: **flexion-extension** and **pronation-supination**. The muscles performing these movements are divided into two groups or compartments: **anterior compartment** and **posterior compartment**. While the primary action of most of these muscles is at the elbow joint, some also act on the shoulder joint.
12. Anterior compartment muscles:
- Biceps brachii muscle:** so named because its origin at the scapula is via two heads; inserts onto the proximal radius (radial tuberosity); the primary and powerful supinators, and also a flexor of the elbow.
 - Brachialis muscle:** origin is anterior surface of distal humerus and insertion proximal ulna; flexor of the forearm.
13. Posterior compartment muscle:
- Triceps brachii muscle:** so named because its origin at the scapula and humerus is via three heads; it inserts onto the most proximal part of ulna (olecranon); the primary extensor of the elbow.

Muscles of the Upper Limb: Forearm

14. The forearm extends from the elbow to the wrist (carpus). Osteologically, it contains the radius and ulna. Two types of movements occur: **flexion-extension** between the forearm

and carpus and of the digits; and **pronation-supination** within the forearm (radial rotation). The flexor and pronator muscles are located within the **anterior compartment** (or flexor-pronator compartment). While the extensor and supinator muscles are located within the **posterior compartment** (or extensor-supinator compartment).

15. The muscles of the anterior compartment are arranged into two layers: a superficial layer and a deep layer. The superficial muscles mostly arise from a common tendon: the **common flexor tendon**. Identify the following superficial muscles:
 - a. **Pronator teres muscle**: insertion lateral surface of distal radius; pronator muscle.
 - b. **Flexor carpi radialis muscle**: insertion at base of 2nd and 3rd metacarpals; flexor and abductor of the hand.
 - c. **Flexor carpi ulnaris muscle**: insertion into medial carpals and at base of 5th metacarpal; flexor and adductor of the hand.
 - d. **Flexor digitorum superficialis muscle**: insertion on middle phalanges 2-5; flexor of phalanges 2-5.
16. The muscles of the posterior compartment are arranged into three functional groups: those acting on the wrist, those acting on digits 2-5 and those acting on digit 1 (thumb). Identify the following muscles:
 - a. **Extensor carpi radialis longus**: origin is the lateral supracondylar ridge of humerus and insertion into the base of the 2nd metacarpal; extends and abducts hand at the wrist.
 - b. **Extensor carpi radialis brevis**: origin is the lateral epicondyle of humerus and insertion into the base of the 3rd metacarpal; extends and abducts hand at the wrist.
 - c. **Extensor digitorum muscle**: origin is the lateral epicondyle of humerus and insertion into dorsal digital expansions and distal phalanges of digits 2-5; extends digits 2-5.
 - d. **Extensor carpi ulnaris muscle**: origin is the lateral epicondyle and posterior border of ulnar and insertion is into the base of 5th metacarpal; extends and adducts hand at wrist.
 - e. Note (observe) that there are several muscles that act on the thumb (digit 1): actions to abduct and extend this digit (NB: you do not need to know their names).

Muscles of the Upper Limb: Hand

17. Note the mass (wad) of muscles located below digit 1. This group is called the **thenar** muscles and they are involved in moving the thumb. (You do not need to learn the individual members of this group.)
18. Note the mass (wad) of muscles located below digit 5. This group is called the **hypothenar** muscles and they are involved in moving the 5th digit. (You do not need to learn the individual members of this group.)
19. Note (observe) that there are several other small muscles that act on the digits from within the hand (NB: you do not need to know their names).

Materials:

- Bones of the axial skeleton including skulls, mandibles, vertebrae, ribs, etc.
- Superficially dissected head and neck specimens showing muscles of mastication and facial muscles
- Superficially and deeply dissected back specimens showing axial muscles
- Bones of the pectoral girdle and upper limb
- Models of shoulder, elbow, wrist and hand joints
- Superficially and deeply dissected shoulder and upper limb specimens showing muscles and joints of shoulder and upper limb

Week 4: Lower Limb Muscles, General Nervous System & Brain

Learning Objectives

1. Understand the major groups of muscles of the lower limb – gluteal region, thigh and leg – and know some important examples of these muscles.
2. To define the major subdivisions of the nervous system.
3. To understand the division of the brain into forebrain, midbrain and hindbrain.
4. To identify the major components of the forebrain and understand their major functions.
5. To identify the major components of the midbrain and hindbrain (cerebellum and medulla oblongata) and understand their major functions.
6. To understand the concept and clinical importance of functional localisation within the cerebral cortex.
7. To identify the components of the ventricular system and meninges of the brain and to understand the role of cerebrospinal fluid (CSF).

Learning Activities

Muscles of the Lower Limb: The Gluteal Region

1. There are two groups of muscles in the gluteal region: a superficial group of large muscles called the **gluteal muscles** and a deep group of smaller muscles called the **lateral rotator group**.
2. The gluteal muscles all originate on the posterior surface of the ilium and insert onto the proximal femur, posterior or lateral surfaces. They can be divided into:
 - a. The **gluteus maximus muscle** - primarily extends the thigh.
 - b. The **gluteus medius and minimus muscles** - abduct the thigh.
3. The **lateral rotator group** of muscles originate from the sacrum (internal surface) or the ischium and insert onto the proximal end of the femur, superior or posterior parts. They all share the function of laterally rotating the thigh. Identify the key member of this group, the **piriformis muscle**.

Muscles of the Lower Limb: The Anterior Hip Flexors

4. These two muscles which are collectively termed the **iliopsoas muscle** arise from the vertebral column and pelvis and have a common insertion (lesser trochanter of the femur) and action (hip flexion). They are:
 - a. The **psoas major muscle** - arising from T12 and lumbar vertebrae
 - b. The **iliacus muscle** - arising from the lateral sacrum and iliac fossa

Muscles of the Lower Limb: The Thigh

5. The muscles of the thigh are divided into **anterior, medial** and **posterior** groups:
 - a. **Anterior group**: the major muscle of this group (**quadriceps femoris muscle**) is so-named because it is made up of four muscle heads which form a common tendon which attaches to the base of the patella and continues to the tibia as the **patellar ligament**. The main function of these muscles is to extend the leg at the knee joint. Identify and learn the four heads of the quadriceps muscle:
 - **Rectus femoris muscle**
 - **Vastus medialis muscle**
 - **Vastus intermedius muscle**
 - **Vastus lateralis muscle**
 - b. **Medial group** or **adductor group**: muscles which occupy the medial compartment of the thigh and all adduct the thigh. All originating on the pubis and inserting onto the proximal part of the femur or tibia (in the case of the gracilis muscle). Identify and learn the following members of this group:
 - **Pectineus muscle**
 - **Adductor longus muscle**

- **Adductor brevis muscle**
 - **Adductor magnus muscle**
 - **Gracilis muscle**
- c. **Posterior group or hamstring muscles.** All originating on the ischium and inserting onto the proximal tibia or fibula. They extend the thigh and flex the leg. This group includes of three muscles:
- **Semitendinosus muscle**
 - **Semimembranosus muscle**
 - **Biceps femoris muscle**

Muscles of the Lower Limb: The Leg

6. The muscles of the leg are grouped into three compartments:
- a. **Anterior group:** observe and learn only the following members of this group:
- **Tibialis anterior muscle:** origin proximal tibia and lateral condyle and inserts onto base of the 1st metatarsal (of the great toe). **Dorsiflexes** foot (turns it upward) and inverts foot (turns it so the sole faces medially).
 - **Extensor digitorum longus muscle:** origin on lateral condyle of tibia and proximal fibula and inserts onto middle and distal phalanges of digits 2-5. Extends the toes and assists in dorsiflexion.
 - **Extensor hallucis longus muscle:** origin on shaft of fibula and interosseous membrane and inserts onto distal phalanx of the great toe (digit 1). Extends the great toe and assists in dorsiflexion.
- b. **Lateral group:** two muscles which are not covered in this course (i.e. do not learn their names or functions). This group is responsible for eversion of the foot
- c. **Posterior group:** observe and learn only the following members of this group:
- **Gastrocnemius muscle:** a two-headed superficial muscle; lateral head arises from around the lateral femoral condyle and medial head from around the medial femoral condyle. See below for insertion and action.
 - **Soleus muscle:** arises from the superior and posterior tibia and fibula. The tendons of the soleus and gastrocnemius muscles fuse to form the calcaneal or Achilles tendon that inserts into the posterior calcaneus. For this reason these muscles are collectively referred to as the **Triceps surae muscle**. The main action of gastrocnemius and soleus muscles (i.e. triceps surae) is **plantarflexion** of the foot.

The Nervous System

7. With your tutor have a discussion about the nervous system and answer the following questions:
- a. What is the difference between grey and white matter?
- b. Where is the boundary between the central and peripheral divisions of the nervous system?
- c. What are the major components of the central nervous system?

Central Nervous System: The Brain

8. In this part of the practical class you are given an opportunity to familiarise yourself with the appearance and names of the gross features of the brain. You will be provided with whole and half (bisected) brain specimens as well as plastic models. Because the whole brains are made of soft tissue and are difficult to obtain, they must be treated with extreme care and gloves must be worn at all times when handling them.

Brain: Cerebral Hemispheres

9. Examine the large cerebral hemispheres, separated by the longitudinal fissure and covered by a highly folded layer of grey matter called the **cerebral cortex**. The cerebral cortex has a very large surface area and, in order to fit into the cranial cavity, it is thrown up into folds (known as **gyri**), separated by grooves (known as **sulci**)

10. On whole and half brains, identify the following sulci and gyri:
- **Central sulcus** – passing downwards on the lateral surface
 - **Lateral sulcus**
 - **Precentral and postcentral gyri** – on either side of the central sulcus
 - **Parieto-occipital sulcus** (medial surface)
 - **Calcarine sulcus** (medial surface).

Now identify the four lobes of the cerebral cortex:

- **Frontal lobe** – anterior to the central sulcus
- **Parietal lobe** – between the parieto-occipital and central sulci
- **Temporal lobe** – inferior to the lateral sulcus
- **Occipital lobe** – posterior to the parieto-occipital sulcus

Note that each lobe of the cerebral cortex is named according to the bone that covers it. What part or lobe of the brain occupies each of the anterior, middle and posterior cranial fossae?

On the half brains identify the **corpus callosum**, a large bundle of white matter that interconnects the two hemispheres.

Brain: Function in the Cerebral Cortex

11. Participate in tutorial discussion about the localisation of function in the cerebral cortex. On specimens try to locate:
- Primary motor area
 - Primary somatosensory area
 - Primary auditory area
 - Primary visual area
 - Motor speech area
 - Receptive speech area

Brain: Thalamus, Hypothalamus, Brainstem and the Cerebellum

12. Examine whole and half brain specimens and identify the following:
- a. The **thalamus** and **hypothalamus** and the relatively small **midbrain** behind them.
 - b. Components of the hindbrain – the **pons**, **cerebellum** and **medulla oblongata** (a continuation of which is the spinal cord).
- Note the following:
- The **hypophysis** (pituitary gland) attaches to the ventral surface of the hypothalamus just behind the **optic chiasm** but it breaks off when the brain is removed from the skull.
 - Together the midbrain, pons and medulla form the **brainstem**.
13. In general terms what are the main functions of the thalamus and hypothalamus, brainstem and cerebellum?

Brain: Cerebrospinal Fluid (CSF) and the Ventricles

14. The ventricular system consists of a series of interconnected spaces within the brain, which contain and produce cerebrospinal fluid (CSF).
- On specimens and models, identify the components of the ventricular system:
- Lateral ventricles (located within each cerebral hemisphere).
 - Interventricular foramen
 - Third ventricle (between the two thalami, the hypothalamus forming its floor).
 - Cerebral aqueduct (passing through the midbrain).
 - Cavity of the fourth ventricle (located between the pons and the cerebellum).
 - Central canal (extending from medulla into spinal cord).
- What is the function of CSF? How does CSF get from the ventricular system out into the subarachnoid space, which surrounds the brain?

Brain: The Meninges

15. Identify the fibrous coverings (**meninges**) of the brain, which are continuous with those of the spinal cord:
- **Pia mater** is a thin layer, which adheres to the brain surface and follows its contours,
 - **Arachnoid mater**, can be seen on the surface of the forebrain, separated from the pia mater by the subarachnoid space, which (in the living) is filled with cerebrospinal fluid (CSF). Major arteries and veins supplying the brain can also be seen to occupy this space,
 - **Dura mater** can be seen lining the inner surface of the skull and reflecting away from it to form:
 - **Falx cerebri** (between the two cerebral hemispheres) and
 - **Tentorium cerebelli** (between the cerebral hemispheres and the cerebellum).

Materials:

- Bones and models of the pelvic girdle and the lower limb.
- Thigh, leg and knee dissections.
- Whole and half brain specimens and models
- Plastinated brainstems and large brainstem models

Week 5: Spinal Cord & Spinal Nerves

Learning Objectives

1. To describe the location, gross features and internal structure of the spinal cord.
2. To describe the formation and functions of spinal nerves.
3. To describe simple spinal reflexes (stretch, withdrawal) and understand their function.
4. To understand the principles of nerve supply to the body wall.
5. To identify the brachial plexus and understand the formation, course & distribution of the major nerves of the upper limb
6. To understand the course and distribution of the major nerves of the lower limb

Learning Activities

Central Nervous System: The Spinal Cord

1. In this part of the practical class you are given an opportunity to familiarise yourself with the gross features of the spinal cord. You will be provided with whole spinal cords and because the spinal cords are made of soft tissue and are difficult to obtain, they must be treated with extreme care and gloves must be worn at all times when handling them.

Spinal Cord: Vertebral Column and Canal

2. Examine an articulated vertebral column and then discuss the following:
 - a. How long is the vertebral canal?
 - b. At what level does the spinal cord end?
 - c. How do the spinal nerves leave the vertebral canal?

You should at some stage visit the anatomy museum and examine the bottle which shows the spinal cord in situ. Try to identify the same structures previously identified in the isolated spinal cord.

Spinal Cord: The Meninges

3. Identify the components of the meninges covering the isolated spinal cord
 - **Pia mater:** adhering to the cord
 - **Dura mater:** the outermost layer
 - **Arachnoid mater:** forms a shiny lining on the inner surface of the dura
 - **Subarachnoid space:** between the arachnoid and pia; filled with cerebrospinal fluid (CSF).

Spinal Cord: Gross Features

4. Examine the isolated spinal cord and the spinal cord in prosected specimens and identify:
 - **Cervical and lumbar enlargements**
 - **Conus medullaris**
 - **Dorsal and ventral roots** and **dorsal root ganglia**
 - **Spinal nerves**
 - **Cauda equina**

How long is the spinal cord?

Spinal Cord: Origin of Spinal Nerves

5. With your tutor, review the internal features of the spinal cord and the formation of spinal nerves. Study models of the cervical spinal cord and identify the:
 - **Body and arch of the vertebra**
 - **Dorsal and ventral horns** and **white matter** of the spinal cord
 - **Dorsal and ventral roots**
 - **Dorsal root ganglion**
 - **Spinal nerve**
 - **Dorsal and ventral rami**

What types of neurons are contained in the dorsal and ventral roots?

Spinal Cord: Reflexes

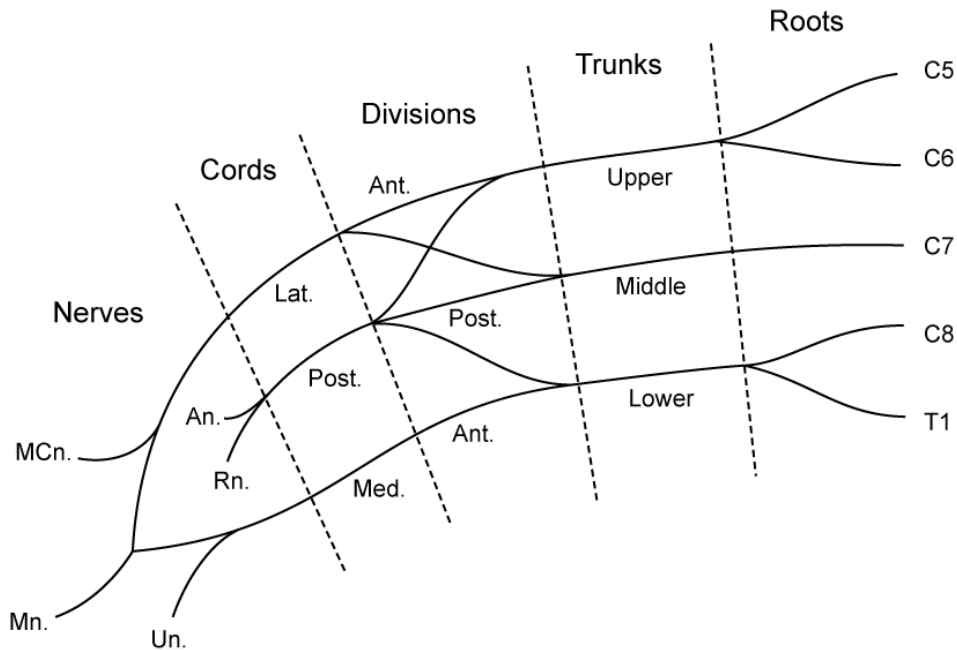
6. Discuss the following with your tutor:
 - a. What is a spinal reflex?
 - b. Draw a diagram of the neurons involved in the **stretch reflex** and the **withdrawal reflex**.
 - c. Demonstrate the knee jerk (stretch) reflex on a colleague. Why is this reflex commonly tested in a physical examination?
 - d. What is the function of the withdrawal reflex?

Peripheral Nervous System: Spinal Nerves and Segmental Nerve Supply

7. Listen to a brief explanation of the segmental (spinal) nerve supply to the trunk and limbs and discuss the following:
 - a. What is a **dermatome**?
 - b. What are the effects of an injury which severs the spinal cord in the thoracic region?
8. On prosected specimens identify **intercostal (thoracic) nerves**, each of which supplies a strip of bone, skin and muscle, which extends around the body wall.

Peripheral Nervous System: The Brachial Plexus

9. Use the schematic diagram below to help you identify the following components of the brachial plexus on prosected specimens of the neck and axilla.
 - **Roots (i.e. ventral rami) of C5 - T1 spinal nerves** (between the scalene muscles).
 - **Upper, middle and lower trunks**
 - **Anterior and posterior divisions**
 - **Medial, lateral and posterior cords**



10. Specifically identify the following branches of the brachial plexus:
 - **Musculocutaneous nerve** (from lateral cord)
 - **Ulnar nerve** (from the medial cord)
 - **Median nerve** (from both medial and lateral cords)
 - **Radial and Axillary nerves** (from the posterior cord)

Note – you **do not** need to identify any other branches of the plexus.

Peripheral Nervous System: Nerves of the Upper Limb

11. On prosected specimens, follow the course of the radial, median and ulnar nerves through the upper limb to the hand. Identify the deep and superficial branches of the radial nerve and then answer the following:
- What are the main muscle groups and areas of skin supplied by each of the above nerves?
 - Which nerve is affected when you hit your 'funny bone'. In this case, where would you expect to feel numbness and weakness?
 - Which nerve is involved in carpal tunnel syndrome?

Peripheral Nervous System: Nerves of the Lower Limb

12. In prosected specimens note the location of the lumbosacral plexus (you do not need to identify its individual components). Identify the following nerves and follow their course through the limb:
- **Femoral nerve** – emerging into the anterior thigh beneath the inguinal ligament
 - **Obturator nerve** – emerging into the medial thigh via the obturator canal
 - **Sciatic nerve** – in the posterior thigh
 - **Tibial nerve** – behind the knee (in the popliteal fossa) & at the ankle
 - **Common fibular (peroneal) nerve** – following the biceps tendon to the lateral side of the leg
13. List the main muscle groups and area of skin supplied by each of the above nerves. What is meant by the term 'sciatica'?

Materials:

- Isolated spinal cords and cross-section models of the spinal cord.
- Deep thorax dissections
- Shoulder, upper limb, pelvic and lower limb dissections

Week 6: Cranial Nerves & Autonomic Nervous System

Learning Objectives

1. To know the general functions of cranial nerves I-XII.
2. To describe the anatomical and functional differences between the somatic and autonomic divisions of the nervous system.
3. To understand the division of the autonomic nervous system (ANS) into parasympathetic and sympathetic components.
4. To list the anatomical and functional differences between the parasympathetic and sympathetic divisions of the ANS.
5. To understand the role of autonomic ganglia, preganglionic and postganglionic neurons.
6. To know the cranial and spinal nerves which contain parasympathetic fibres and understand their function.
7. To recognise the major components of the sympathetic nervous system and understand their function.

Learning Activities

Peripheral Nervous System: Cranial Nerves

1. Cranial nerves like spinal nerves are part of the peripheral nervous system. Cranial nerves differ from spinal nerves in that:
 - They arise from the brain and brainstem and not the spinal cord.
 - They exit the bony enclosure of the central nervous system via foramina in the base of the skull rather through intervertebral foramina.
 - There are only 12 pairs of cranial nerves while there are 31 pairs of spinal nerves.
2. The twelve pairs of cranial nerves (CN) are numbered using roman numerals from I - XII. On models and brain specimens, try to identify each of the cranial nerves as they emerge on the ventral surface of the brain.

Abbrev.	Name	Function/Origin
CN I	Olfactory nerve	Smell
CN II	Optic nerve	Vision (covered in week 8)
CN III	Oculomotor nerve	Ventral surface of the midbrain
CN IV	Trochlear nerve	Dorsal surface of midbrain
CN V	Trigeminal nerve	Lateral pons, largest nerve and has 3 branches: CN V ₁ - Ophthalmic nerve CN V ₂ - Maxillary nerve CN V ₃ - Mandibular nerve
CN VI	Abducens nerve	Pontomedullary junction
CN VII	Facial nerve	Pontomedullary junction (lateral side)
CN VIII	Vestibulocochlear nerve	Pontomedullary junction (lateral to CN VII)
CN IX	Glossopharyngeal nerve	Medulla (lateral to olive)
CN X	Vagus nerve	Lateral medulla (below CN IX)
CN XI	Accessory nerve	Lateral medulla (below CN X) and upper cervical spinal cord
CN XII	Hypoglossal nerve	Medulla medial to olive

Cranial Nerves: Cranial Foramina

3. Examine the cranial fossae of skulls and identify the foramina through which the cranial nerves enter or leave the cranial cavity:
 - **Foramina of the Cribriform plate** – olfactory nerves (CN I)
 - **Optic canal** – optic nerve (CN II)
 - **Superior Orbital fissure** – oculomotor, trochlear, ophthalmic and abducens nerves (CN III, IV, V₁ & VI)
 - **Foramen rotundum** – maxillary nerve (CN V₂)
 - **Foramen ovale** – mandibular nerve (CN V₃)
 - **Internal acoustic meatus** – facial and vestibulocochlear (CN VII & VIII)
 - **Jugular foramen** – glossopharyngeal, vagus and accessory nerves (CN IX, X & XI)
 - **Hypoglossal canal** – hypoglossal nerve (CN XII)

Cranial Nerves: Function

4. Participate in a general discussion concerning the general function(s) of each of these nerves. Consider the effects of damage to the:
 - Trigeminal nerve (CN V)
 - Facial nerve (CN VII)

Autonomic Nervous System

5. The autonomic nervous system (ANS) functions to regulate the activity of the viscera by supplying motor fibres to smooth and cardiac muscles and glands. On the basis of function it is divided into two divisions – parasympathetic and sympathetic, which have opposing effects. The parasympathetic division functions to conserve and restore energy, whereas the sympathetic division enables the body to cope with stress ('fear, flight and fight').

Using posters provided compare the following features of parasympathetic & sympathetic divisions:

- a. Origin of preganglionic fibres from the central nervous system
- b. Location of their ganglia
- c. Distribution (structures supplied by each system)

Autonomic Nervous System: The Parasympathetic Division

6. Sometimes referred to as craniosacral outflow. The cranial portion of the division includes parasympathetic fibres within the **oculomotor, facial, glossopharyngeal** and **vagus nerves**, while the sacral portion of the division includes **pelvic splanchnic nerves** arising from the sacral spinal cord within the pelvic cavity.

The oculomotor nerve (CN III) supplies the smooth muscles of the eye (sphincter pupillae and ciliary muscles) and the facial (CN VII) and glossopharyngeal (CN IX) nerves together supply the glands of the head – no more detail is required for these nerves.

7. The largest and most important parasympathetic nerve is the **vagus nerve** (CN X), which supplies the viscera of the thorax and abdomen. It contains preganglionic parasympathetic fibres that end on ganglia in the walls of the target organs.

Identify the following features on models and prosected specimens:

- In the neck, the **right and left vagus nerves** can be found posterior to the **internal and common carotid arteries**. In the intact specimen the vagus nerve, internal jugular vein and internal carotid artery travel together within the carotid sheath, but the connective tissue of the sheath is removed during the dissecting process).
- Follow the course of the vagus nerves down into the thorax, and observe how they intermingle with each other to form the **oesophageal plexus**, which surrounds the oesophagus.
- Fibres from the oesophageal plexus continue into the abdomen to join plexuses on the front of the aorta. Identify the largest of these plexuses, the **coeliac plexus**, in abdomen specimens. From here fibres hitch a ride along the major arteries to reach the

abdominal organs.

Consider the consequences of damage to one vagus nerve in the neck. Would it have a significant effect on heart rate and GIT function? Why?

8. The **pelvic splanchnic nerves** carry parasympathetic fibres from the sacral levels (S2-4) of the spinal cord to the pelvic viscera (lower part of the gastrointestinal system and urogenital structures). With the help of your tutor identify these nerves on the posters and in deep dissections of the pelvis

Autonomic Nervous System: The Sympathetic Division

9. Sometimes referred to as the thoracolumbar outflow because it originates from cells in the thoracic and upper lumbar segments of the spinal cord.

Identify the following features on models and prosected specimens:

- **Sympathetic trunk and sympathetic ganglia**
 - Grey & white rami communicantes – connecting the sympathetic trunk to spinal nerves.
 - **Cervicothoracic (stellate) ganglion** – formed by fusion of the C7, C8 and T1 ganglia and vulnerable to compression by tumours on the apex of the lung.
 - **Superior cervical ganglion** – contains cell bodies postganglionic fibres which supply structures in the head
 - **Greater splanchnic nerve** - made up of preganglionic fibres which terminate in the coeliac ganglion
 - Coeliac ganglion –the largest prevertebral ganglion - contains cell bodies of postganglionic fibres that supply the foregut structures
10. Discuss with your tutor the effects of stimulation of the sympathetic division on:
 - the lungs and bronchi?
 - the heart and blood vessels?

Materials:

- Whole and half brain specimens and models
- Plastinated brainstems and large brainstem models
- Sagittal head and neck specimens
- Plastinated head/pharynx specimens
- Deep thorax dissections

Week 7: Eye & Ear

Learning Objectives

1. To recognise the boundaries and major contents of the orbit (eye, optic nerve, extraocular muscles and lacrimal gland).
2. To describe the basic structure of the eye and understand the function of each of its major components.
3. To describe the basic structure of the retina and how light waves are detected and transmitted to the optic nerve
4. To identify the fovea and understand its significance
5. To understand the division of the ear into external, middle and internal parts
6. To identify the tympanic membrane, ossicles and windows of the middle ear and to understand the function of these structures.
7. To locate the auditory tube and understand its function.
8. To briefly describe the bony and membranous labyrinths
9. To understand the role of the cochlear duct in hearing
10. To understand the role of the semicircular canals, utricle and saccule in the maintenance of equilibrium

Learning Activities

Eye: The Orbit

1. On the skulls examine the orbits. Note the thick, protective outer rim and the thin superior and medial walls. Identify the **optic canal**, through which the optic nerve passes on its way to the brain and the **superior orbital fissure**, through which other nerves and blood vessels enter the orbit.

In the dissected specimens identify the **eyeball**, with the **extraocular muscles** attached to its exterior surface, the **optic nerve** which transmits sensory information from the retina to the brain and **lacrimal gland** located superolaterally beneath the upper eyelid. What is the function of the lacrimal gland?

Eye: The Extraocular Muscles

2. Examine the dissected orbits and orbit models and observe the extraocular muscles as a group and note their positions in inserting onto the eye.

Note that four of these muscles (the rectus muscles; see below) all arise from a common tendinous ring which encircles the optic canal and superior orbital fissure on the posterior wall of the orbit.

Refer to the table below and specifically identify each extraocular muscle and discuss its action.

Muscle	Action
Superior rectus muscle	elevation and adduction (for looking up and in)
Inferior rectus muscle	depression and adduction (for looking down and in)
Medial rectus muscle	adduction of the eyeball (for looking in)
Lateral rectus muscle	abduction of the eyeball (for looking out)
Superior oblique muscle	depression and abduction (for looking down and out)
Inferior oblique muscle	elevation and abduction (for looking up and out)

Eye: The Eyeball

3. Examine isolated eyeballs and models of the eyeball and identify its outer fibrous coat

which is formed posteriorly by the **sclera** (white) and anteriorly by the **cornea** (clear).

The sclera is lined by a vascular layer called the **choroid** which is continuous anteriorly with the **ciliary body** (muscle) and the **iris diaphragm**, in the centre of which is an opening, the **pupil**, through which light enters the eye. The **lens** is attached by a ligament to the ciliary muscle.

Observe the eye of a colleague and identify the **cornea**, **sclera**, **iris** and **pupil**. Note the how the curvature of the cornea differs from that of the sclera. The sclera is covered by a fine vascular membrane called the **conjunctiva**.

Demonstrate the pupillary light reflex on a colleague. What is the function of this reflex?

What is 'accommodation'? Observe what happens to the pupils of a colleague when they focus on a near object after looking into the distance.

Eye: The Retina

- Note on the eye models that behind the lens the choroid layer is lined by the **retina**, the nervous, or receptive, layer of the eye. Nerve fibres from the retina leave the eye through the **optic disc** to form the **optic nerve**.

Examine the histological structure of the retina using photographs provided. In the image of peripheral retina, identify the:

- **Ganglion cell layer**
- **Inner nuclear (bipolar) cell layer**
- **Photoreceptor cell layer**

How do cone and rod photoreceptors differ in function?

Compare this image with a section through the **fovea** and note how the ganglion and bipolar cells have been cleared to the side to allow the light to pass unimpeded through to the photoreceptors.

Where in the retina is the fovea located and what is its function?

What type of photoreceptor is located at the fovea?

Eye: The Visual Pathway

- Examine brain specimens and identify the **optic nerves**, **chiasm** and **tract** and the **visual cortex**.

In your own time, complete the table below regarding the function of the eye and visual system:

Structure	Function
Cornea	
Sclera	
Choroid	
Iris	

Ciliary Muscle	
Lens	
Retina	
Fovea	
Optic Disc	
Optic Nerve	
Optic Chiasm	
Optic Tract	
Visual Cortex	

Ear: The Temporal Bone

6. Examine skulls and identify the **petrous** portion of the **temporal bone**. Why is it called 'petrous'? Identify the **internal** and **external acoustic meatuses** and indicate the approximate location of the inner and middle parts of the ear. Identify the mastoid process.

Ear: The Outer, Middle and Inner Ear

7. Examine models of the ear and identify each of the following components of the outer and middle ears:

- **External acoustic meatus**
- **Tympanic membrane**
- **Ossicles (malleus, incus and stapes)**
- **Oval window**
- **Auditory tube** - where does it lead to and what is its function?

Identify the parts of the bony labyrinth:

- **Vestibule**
- **Cochlear**
- **Semicircular canals** and their **ampullae**

What type of fluid is contained inside the bony labyrinth?

Ear: Membranous labyrinth

8. On the large demonstration model identify the parts of the membranous labyrinth:

- **Semicircular ducts** and their **ampullae**
- **Utricle & saccule**
- **Cochlear duct**

Locate the **Organ of Corti** in the cochlear duct.

Ear: Organ of Corti

9. On photographs of the cochlear duct (provided) identify the:

- **Cochlear duct**
- **Scalae vestibuli and tympani**
- **Vestibular membrane**
- **Tectorial and basilar membranes and**
- **Hair cells.**

10. How are sound waves transmitted to the inner ear and how they are converted by the Organ of Corti into a nervous impulse?

What type of receptors are located in the utricle, saccule and semicircular canals? Briefly discuss the role of these receptors in the maintenance of balance.

Materials:

- Skulls and temporal bones
- Brain, eye, orbit and ear models
- Photographs of retinas and retinal vessels

Week 7: Revision Lab (11am-2pm or 2-5pm Thursday 11/09/2014)

- The Revision Lab will cover the material addressed in the practical classes of weeks 1 to 7 (i.e. General Anatomy through to Eye and Ear).

Week 8: Spot Test No.1 (1-2pm or 2-3pm Wednesday 17/09/2014)

- Note that there will be no lectures or practical classes in week 8.
- Two iterations of Spot test No.1 will be run in the dissection room during the last hour of the normal Wednesday 11am-2pm class and the first hour of the normal 2-5pm class (i.e. from 1-2pm and 2-3pm).
- Students who normally attend the 11am-2pm practical class are required to attend the 1-2pm test, while those who normally attend the 2-5pm practical class are required to attend the 2-3pm test. A role will be taken at the door of the dissecting room and all students must attend at the time they have been allocated.
- Spot test no.1 will cover the material addressed in the practical classes of weeks 1 to 7 (i.e. General Anatomy through to Eye and Ear).

Week 9: Cardiovascular System

Learning Objectives

1. To identify the pericardium and understand its function.
2. To identify the major structural features and internal divisions of the heart and the characteristics of each.
3. To know the position and significance of the pacemaking/conducting tissue of the heart
4. To identify the major arteries supplying blood to the heart.
5. To describe the overall plan of the circulatory system and to understand the concept of the pulmonary and systemic circulations.
6. To identify the carotid arteries and to describe in basic terms the vascular supply of the head and neck.
7. To identify the subclavian artery and to describe in basic terms the vascular supply of the upper limb.
8. To identify the abdominal aorta and to describe in basic terms the vascular supply of the abdomen, pelvis and lower limb.
9. To identify the major tributaries of the superior vena cava (i.e. jugular, subclavian brachiocephalic veins) and describe in basic terms the venous drainage of the head, neck and upper limb.
10. To identify the major tributaries of the inferior vena cava and to describe in basic terms the venous drainage of the abdomen, pelvis and lower limb.

Learning Activities

Heart: The Pericardium

1. The heart is enclosed in a membranous sac called the pericardium. Identify the following layers of the pericardium:
 - **Fibrous pericardium** (a tough external sac which extends from the great vessels and the fascia surrounding the trachea to the central tendon of the diaphragm).
 - **Parietal serous pericardium** (lines the fibrous pericardium).
 - **Visceral serous pericardium** (covers the surface of the heart).Note the visceral and parietal layers of the pericardium are separated by a thin film of fluid.

Heart: Position and External Features

2. The heart sits on the central tendon of the diaphragm and lies anterior to the TV6-9 and posterior to the body of the sternum and 2nd to 6th costal cartilages. Identify the following external features of the heart:
 - **Apex** (which projects to the left and inferiorly).
 - **Base** (where great vessels enter and leave the heart).
 - **Anterior** (sternocostal), **Inferior** (diaphragmatic), and **Pulmonary** surfaces.

Heart: Internal Features

3. Examine the internal features of the heart. Note that the heart is made up of four chambers which are divided by two walls or septa. On the isolated heart specimens and the heart models identify these structures:
 - **Right Ventricle**
 - **Right Atrium**
 - **Left Ventricle**
 - **Left Atrium**
 - **Interventricular septum**
 - **Interatrial septum**
4. Specifically examine the interior of the right atrium and identify the following features:
 - **Openings of the superior and inferior vena cavae**
 - **Fossa ovalis** (remnant of the fetal foramen ovalis)

- **Right atrioventricular orifice** (orifice between right atrium and ventricle)
 - **Tricuspid valve**
5. Specifically examine the interior of the right ventricle and identify the following features:
- **Papillary muscles**
 - **Chordae tendineae** (collagenous bands attaching to the apices of the papillary muscles to the margins of the tricuspid valve leaflets)
 - **Semilunar pulmonary valve**
 - **Pulmonary trunk** (emerging from the ventricle)
6. Specifically examine the interior of the left atrium and identify the following features:
- **Pulmonary veins** (four veins opening into the left atrium)
 - **Interatrial septal wall**
 - **Left atrioventricular orifice** (orifice between left atrium and ventricle)
 - **Bicuspid (mitral) valve** (valve of the left atrioventricular orifice)
7. Specifically examine the interior of the left ventricle and identify the following features:
- **Anterior and posterior papillary muscles** (one for each mitral valve leaflet)
 - **Chordae tendineae**
 - **Semilunar aortic valve**
 - **Aorta** (emerging from the left ventricle)

Note the difference in the thickness of the left and right ventricle walls. What is a 'hole in the heart'? What are the functions of the atrioventricular valves and the chordae tendineae?

Heart: Pacemaking/Conducting Tissue of the Heart

8. The heart will beat on its own, even if all nerves to it are cut because it has its own intrinsic nervous system, known as the pacemaking or conducting system. Identify the approximate positions of the following features:
- **Sinatrial node** (in the upper wall of the right atrium)
 - **Atrioventricular node** (medial wall of right atrium)
 - **Atrioventricular bundle** (in the interventricular septum)

What is the function of the extrinsic nerves to the heart?

Pulmonary and Systemic Blood Circulations

9. Briefly review the roles of the pulmonary and systemic circulations and consider the arrangement of pulmonary and systemic arteries and veins and the flow of blood to and from the heart.

Arterial Blood Supply: Heart

10. The heart is supplied by the first two branches of the aorta, the right and left coronary arteries. Identify these vessels in the isolated heart specimens and models:
- **Right coronary artery** (passes behind the pulmonary trunk to the coronary groove)
 - **Left coronary artery** (runs between the pulmonary trunk and the left auricle and supplies a greater volume of the myocardium than the right coronary artery)

What is a myocardial infarction?

Arterial Blood Supply: Head and Neck

11. The main branches to the head and neck are the right common carotid artery (arises from the brachiocephalic branch of aortic arch) and the left common carotid artery (arises directly from the aortic arch) and the vertebral artery (branch of subclavian). Identify the following arteries:
- **Arch of the aorta**
 - **Brachiocephalic trunk** (divides into right common carotid and subclavian arteries)

- **Right and left common carotid arteries**
- **External carotid artery** (supplies the face and external head)
- **Internal carotid artery** (supplies the brain via anterior and middle cerebral arteries)
- **Vertebral artery** (the first branch of the subclavian artery)

Branches of the vertebral arteries anastomose (unite) with branches of the internal carotid arteries on the base of the brain forming the cerebral arterial circle (commonly known as the **Circle of Willis**). Identify this circle on the base of the brain (Note: you do not need to actually name its component arteries at this stage).

Arterial Blood Supply: Upper Limb

12. The main branches to the upper limbs arise from the right and left subclavian arteries. Identify the following arteries:

- **Right subclavian artery** (arises from the brachiocephalic trunk)
- **Left subclavian artery** (arises directly from the aortic arch)
- **Axillary artery** (continuation of the subclavian artery, courses through the axilla (armpit) to reach the upper limb)
- **Brachial artery** (continuation of the axillary artery - courses with the humerus supplying arm muscles, skin and bone)
- **Ulna artery** (supplies the flexor muscles of the forearm and hand)
- **Radial artery** (supplies the extensor muscles of the forearm)

Arterial Blood Supply: Abdomen and Pelvis

13. The branches to the abdomen and pelvis arise from the abdominal aorta. Identify the following arteries:

- **Coeliac trunk** (supplies foregut structures such as the stomach, liver and spleen)
- **Superior mesenteric artery** (largely supplies the small intestine and the proximal portion of the large intestine)
- **Inferior mesenteric artery** (largely supplies the distal portion of the large intestine)
- **Renal arteries** (paired; supplies the kidneys)
- **Common iliac arteries** (divide into internal and external branches)
- **Internal iliac arteries** (supply pelvic walls and viscera)
- **External iliac arteries** (gives off branches to the abdominal wall before passing under the inguinal ligament to supply mainly the lower limb).

Arterial Blood Supply: Lower Limb

14. The main branches to the lower limb arise from the femoral artery, which is the continuation of the external iliac artery as it passes under the inguinal ligament of the pelvis. Identify the following arteries:

- **Femoral artery** (in the anterior thigh).
- **Popliteal artery** (continuation of the femoral artery behind the knee)
- **Anterior tibial artery** (supplies anterior leg)
- **Posterior tibial artery** (supplies posterior leg and is the major supply to the foot)

Venous Drainage: Systemic and Portal

15. Blood from the limbs and head drains via deep and superficial (skin) veins. In general deep veins accompany arteries and share the same name. Blood from the upper limb, head, neck and thorax drain into the superior vena cava, while blood from the lower limb, abdomen and pelvis drains into the inferior vena cava. Identify the major veins draining the head, neck and upper limb:

- **External jugular vein** (draining the scalp and face)
- **Internal jugular vein** (collecting blood from the skull, brain, superficial parts of the face and much of the neck)
- **Right and left subclavian veins**
- **Right and left axillary veins**

- **Right and left brachiocephalic veins** (receives the jugular and subclavian veins)
- **Superior vena cava**

16. Identify the major veins draining the abdomen, pelvis and lower limb:

- **Portal vein** – what is its function?
- **Inferior vena cava**
- **Common iliac vein**
- **Internal iliac vein**
- **External iliac vein**
- **Femoral vein**
- **Great saphenous vein**

17. Identify the superficial veins of the upper limb on yourselves:

- **Cephalic vein** (along lateral side of upper limb - usually drains into axillary vein)
- **Basilic vein** (along medial side of upper limb - drains into the brachial vein)
- **Median cubital vein** (joining cephalic and basilic in cubital fossa, i.e. front of elbow)

Note the variation between individuals in the pattern of superficial veins. The little swellings on the veins are valves. Can you demonstrate how they function?

Materials:

- wet prosections of the thorax
- wet prosected hearts and heart models
- radiographs of the chest
- wet prosections of the head, neck, thorax and upper limb
- wet superficial and deep abdominal and posterior abdominal wall prosections.
- wet prosections of the pelvis and lower limb.

Week 10: Respiratory System

Learning Objectives

1. To examine the structure of the external nose and identify the anterior (nares) and posterior (choanae) openings of the nasal cavity.
2. To define the vestibule, respiratory and olfactory areas of the nasal cavity and identify the major structural features of the nasal cavity including the conchae, meatuses.
3. To identify the paranasal sinuses and their openings into the nasal cavity.
4. To identify and examine the cartilaginous skeleton of the larynx and discuss the structure of the larynx, and the role of the larynx in breathing and speech.
5. To identify the bones, cartilages and joints of the thoracic cage, the diaphragm and the intercostal and accessory muscles of respiration and to describe the actions of these bones, joints and muscles during lung ventilation.
6. To define the boundaries of the thoracic cavity and its division into right and left thoracic regions and the mediastinum.
7. To identify components of the trachea, bronchi, lungs and lung hila.
8. To identify the components of the pleural sac and discuss its functional significance and the relationship of visceral and parietal pleura to the lung.
9. To identify the major features of the respiratory system on skull and chest x-rays.

Learning Activities

Upper Respiratory System: The External Nose

1. Examine the dissected specimens and dried skulls and note that the skeleton of the external nose is comprised largely of cartilage. On the dried skull the anterior bony opening, onto which the cartilages are attached, is known as the **piriform aperture**.

Upper Respiratory System: The Nasal Cavity

2. The anterior openings of the nasal cavity are the **nares**, while the posterior openings are the **choanae**. The nasal cavity is divided in the midline by the **nasal septum**. The medial wall of each half of the cavity is flat and smooth while the lateral wall has three bony elevations known as **nasal conchae**. Identify the following features:
 - **Nasal vestibule** (anteroinferior region lined with skin and bearing coarse hairs).
 - **Olfactory region** (posterosuperior lateral wall, opposing medial wall and intervening roof).
 - **Respiratory region** (the remainder of the nasal cavity).

Lateral wall:

- **Ethmoid bone**
(Superior nasal concha & meatus)
(Middle nasal concha & meatus)
- **Inferior nasal concha bone & meatus**

Medial wall (nasal septum):

- **Ethmoid bone**
- **Vomer bone**
- **Nasal septal cartilage**

Roof:

- **Ethmoid bone**
(cribriform plate and foramina)

Floor:

- **Palatine bone**
- **Maxilla bone**

Upper Respiratory System: The Paranasal Sinuses

3. The paranasal sinuses are large air cells within bones that surround the nasal cavity. They are lined with respiratory epithelium and drain into the nasal cavity via various ducts. What are causes and symptoms of inflammation of these sinuses (sinusitis)? Why do you usually get a running nose when you cry?

Upper Respiratory System: The Larynx

4. The larynx extends from the back of the tongue to the top of the trachea (from CV3-6). It is

larger in males than females and is comprised of a cartilaginous skeleton (with associated joints, ligaments and muscles) and is lined with secretory mucosa. Identify the following laryngeal cartilages:

- **Epiglottic cartilage** (leaf-shaped)
- **Thyroid cartilage**
- **Cricoid cartilage**
- **Arytenoid cartilages** (triangular pyramid-shaped)

Identify the following laryngeal features:

- **Laryngeal inlet**
- **Vestibular folds**
- **Vocal folds** (overlies the vocal ligament)
- **Rima glottis** (space between vocal folds)

Lower Respiratory System: The Thorax

5. The remainder of the respiratory system, other than the very top of the trachea, is located within the thorax. The walls of the thorax are comprised of bone, cartilage and muscle and the cavity within the walls is divided into three longitudinal regions (right thoracic region, mediastinum and left thoracic region). The muscles and associated joints of the thorax function in lung ventilation by increasing and decreasing the capacity of the thoracic cavity.

Review the skeleton of the thorax and identify the following:

- **12 thoracic vertebrae** (notice the articular facets for ribs on the body and transverse processes)
- **12 ribs** and their hyaline **costal cartilages**
- **Typical rib (head, neck, tubercle, shaft, posterior angle)**
- Ribs 1-7 ("true ribs" connected to the sternum by costal cartilages).
- Ribs 8-10 ("false ribs" connected to the sternum via suprajacent costal cartilages).
- Ribs 11 & 12 ("floating ribs" not connected to the sternum at all).
- **Sternum**
Manubrium (articulates with clavicle and 1st and 2nd costal cartilages).
Sternal body and sternal angle (manubriosternal joint) – articulates with 2nd to 7th costal cartilages.
Xiphoid process.

Identify the muscles of the thorax:

- Muscular **Diaphragm** and its **central tendon, vena caval, oesophageal** and **aortic openings**.
- **External** and **internal intercostal muscles**.

Lower Respiratory System: The Trachea, Bronchi and Lungs

6. The trachea enters the thorax via the thoracic inlet and then bifurcates into the right and left main bronchi within the mediastinum. These bronchi deliver air to the lungs via hila on their medial (mediastinal) surfaces. Within each lung, the main or principal bronchi undergo numerous divisions to supply the terminal parts of the respiratory tree (i.e. the alveolar sacs).

Identify the major airways:

- **Trachea** (from CV6 to TV5, comprised of stacked U-shaped cartilages anteriorly and trachealis muscle posteriorly).
- **Tracheal bifurcation**
- **Right main bronchus** (wide, short and vertical, divides into upper, middle and lower lobar bronchi).
- **Left main bronchus** (thin, long and horizontal, divides into upper and lower lobar bronchi).

Identify the lungs:

- **Apex, base, anterior, posterior and inferior borders.**
- **Costal, diaphragmatic and medial (with mediastinal & vertebral parts) surfaces.**
- **Right lung**
Oblique and horizontal fissures, and upper, middle and lower lobes.
Hilum (right main and right upper lobar bronchi and pulmonary vessels).
- **Left lung**
Oblique fissure, and upper and lower lobes.
Hilum (left main bronchi and pulmonary vessels).

Lower Respiratory System: The Pleura

7. The pleura is a thin sheet of secretory tissue which lines the inside of the right and left thoracic regions (termed parietal pleura) and at the point where the bronchi and pulmonary vessels emerge from the mediastinum to enter the lung hilum, it reflects onto the surface of the lung (termed visceral pleura). Between the two layers of the pleura is a thin space or cavity which in life contains fluid. Identify the following components of the pleura:
- **Parietal pleura**
 - **Visceral pleura** (extends into the lung fissures)

What is the function of the pleural sacs? What would happen if air entered the pleural cavity? How would this affect lung ventilation?

Lower Respiratory System: The Radiographs

8. Study skull x-rays and identify the **paranasal sinuses** and the **nasal cavity**. Identify **thoracic vertebrae, ribs, sternum, diaphragm, mediastinal (heart) shadow, trachea, main bronchi** and lung hilar shadows on plain chest x-rays and bronchiograms.

Materials:

- Typical ribs, sternum and thoracic vertebrae
- Dissections of the head, neck and torso showing, larynx, trachea, diaphragm and intercostal muscles
- Isolated lung specimens.
- Radiographs of the skull, chest and bronchiograms.

Week 11: Digestive System

Learning Objectives

1. To identify the boundaries components and regions of the mouth, and to describe the number and arrangement of teeth, indicating the typical features of a tooth and how teeth are specialized for different functions.
2. To describe the gross surface features of the tongue, and the position, ducts and openings of the parotid, submandibular and sublingual salivary glands.
3. To identify the components of the palates and oropharyngeal isthmus, and the divisions, internal features of the pharynx.
4. To identify the oesophagus.
5. To identify the gross divisions, surfaces, borders, position and internal features of the stomach.
6. To identify position, lobes and surfaces of the liver. To identify the porta hepatis and the structures within it. To describe the functions of the liver and indicate how liver disease may impair those functions.
7. To identify the components of the extrahepatic biliary apparatus including the gall bladder and the course and relations of the bile duct.
8. To identify the parts of the pancreas and to describe its duct system and function.
9. To identify and describe the position, parts, gross features and disposition in the abdominal and pelvic cavities of the small and large intestines and describe their appearance in barium meal radiographs.

Learning Activities

Upper Digestive System: The Mouth

1. The mouth extends from the oral fissure (between the lips) to the oropharyngeal isthmus. It is comprised of a small vestibule (region between the lips/checks and the gums, alveolar arches and teeth) and the larger oral cavity proper (region inside the gums, alveolar arches and teeth). Identify the external mouth and vestibule:
 - **Upper and lower lips.**
 - **Philtrum** (shallow vertical groove above the centre of in the upper lip).
 - **Alveolar/dental arches**
 - **Crown** and **root of tooth** (typical features of all teeth)
 - **Incisor, canine, premolar and molar teeth**
 - **Oral cavity proper:**
 - **Hard palate** (anterior oral cavity roof formed by the maxillary and palatine bones).
 - **soft palate** (posterior oral cavity roof form by several palatine muscles).
 - **Oral cavity floor** (formed by the anterior tongue and the reflection of the mucosa from the tongue's inferior surface to the internal surface of the mandible).
 - **Oropharyngeal isthmus** (separates the oral cavity proper from the oropharynx).What are “milk teeth”? and what are “wisdom teeth” and why do they impact?

Upper Digestive System: The Tongue

2. The tongue is a large muscle of the oral cavity which is described as having a root, an apex and a dorsum. The dorsum is divided into an anterior oral part and a posterior pharyngeal part by a prominent V-shaped groove termed the sulcus terminalis. Identify the following features:
 - **Lingual papillae (4 types):**
 - **Filiform papillae** (all over presulcal tongue, do not contain taste receptors)
 - **Fungiform papillae** (scattered over presulcal tongue)
 - **Vallate papillae** (immediately anterior to sulcus terminalis)
 - **Foliate papillae** (corrugations on the lateral edges of the tongue)
 - **Sulcus terminalis**
 - **Lingual tonsil** (multiple lymphoid nodules embedded in the posterior part).

- **Intrinsic muscles of the Tongue** (alter the shape of the tongue)
- **Extrinsic muscles of the Tongue** (alter the position of the tongue and stabilise it)

How does the tongue assist in swallowing and speech? What is the function of the lingual tonsil? Are there other nearby structures which serve a similar function? Why are they located in this region?

Upper Digestive System: The Salivary Glands

3. The salivary glands are positioned around the mouth and produce secretions which enter the oral cavity via various ducts. Identify the following:
 - **Parotid gland** (below the external acoustic meatus between the mandible and sternocleidomastoid muscle)
 - **Parotid duct** (pierces the cheek muscle and opens into the vestibule opposite the 2nd upper molar crown)
 - **Sublingual gland** (lies in the floor of the mouth and opens directly by multiple ducts)
 - **Submandibular gland**
 - **Submandibular duct** (opens in the floor of the mouth)

Upper Digestive System: The Soft Palate and Pharynx

4. The soft palate forms part of the oral cavity roof as well as the oropharyngeal isthmus which separates the oral cavity from the pharynx. The pharynx is divided into three parts based on the structures which lie immediately anterior to it. These are the nasopharynx (behind the nasal cavity), the oropharynx (behind the oral cavity) and the laryngopharynx (behind the larynx). Identify the following:
 - **Soft palate**
 - **Nasopharynx** (behind nasal cavity and above the soft palate)
 - **Pharyngeal opening of the auditory tube** and tubal tonsils.
 - **Oropharynx** (from the soft palate to the upper border of the epiglottis).
 - **Palatine tonsil** (chief component of Waldeyer's ring - a protective annulus of lymphoid tissue around the entrance to the digestive and respiratory tracts).
 - **Laryngopharynx** (extending from the upper border of the epiglottis to the lower border of cricoid).
 - **Laryngeal inlet**

What is the function of the soft palate?

Upper Digestive System: The Oesophagus

5. The oesophagus is approximately 25cm long continuing on from the laryngopharynx (CV6), coursing through the neck and thorax and into the abdomen through one of the diaphragm apertures and terminating at the stomach cardia. Identify the following features:
 - **Cervical, thoracic and abdominal parts of the oesophagus**

Lower Digestive System: The Stomach

6. The stomach is the most dilated portion of the digestive system with a capacity of approximately 1500ml. It is positioned in the upper abdomen beneath the left dome of the diaphragm and has a thick muscular wall. Identify the following features:
 - **Greater and lesser curvatures** (left and right borders of the stomach)
 - **Greater omentum** (attached to the greater curvatures).
 - **Cardia, fundus, body and pyloric parts.**
 - **Cardiac opening/orifice** (junction between oesophagus and stomach)
 - **Pyloric opening/orifice** (junction between stomach and duodenum).
 - **Pyloric sphincter** (muscular ring which encircles the orifice).

What is the function of the greater omentum?

Lower Digestive System: The Liver

7. The liver is located in the upper abdomen beneath the right dome of the diaphragm. Its upper parietal or diaphragmatic surface is smooth and convex and is related to the diaphragm whereas its lower visceral or inferior surface contains impressions and tubercles and is related to various abdominal organs. A sharp inferior border separates the two surfaces. Identify the following features:

- **Right, left, quadrate and caudate lobes**
- **Inferior vena cava**
- **Porta hepatis** (where structures enter and leave the liver)
- **Portal vein** (drains the alimentary system, 70% of the liver blood supply).
- **Hepatic artery** (from the aorta via various branches, 30% of liver blood supply).
- **Hepatic duct** (drains the liver of bile).
- **Gall bladder** (stores bile)
- **Bile duct** (transports bile from the gall bladder to the duodenum).

What is a common cause of liver disease in our society? What are gallstones? What would happen if a gallstone became stuck in the bile duct?

Lower Digestive System: The Pancreas

8. The pancreas is a large glandular structure of the abdomen located at the LV1-2 vertebral levels. It lies against the posterior wall of the abdomen. Identify the following features:

- **Head** (the part which is bounded by the duodenum)
- **Neck**
- **Body** (the majority of the pancreas)
- **Tail** (the left tip of the pancreas which is related to the spleen)

What are the functions of the pancreas? Where do the pancreatic ducts empty into the alimentary canal?

Lower Digestive System: The Small Intestine

9. The small intestine is comprised of three parts: the duodenum, jejunum and ileum. The duodenum is the initial and shortest part of the small intestine. It is located in the upper abdomen and is a retroperitoneal structure that surrounds the head of the pancreas. The jejunum and ileum are the long 2nd and 3rd parts of the small intestine (5-8m in length). They are suspended from the posterior wall of the abdomen by a sheet of tissue termed the mesentery. Identify the following features:

- **Pyloric constriction** (overlies the sphincter and its orifice and represents the end of the stomach and the beginning of the duodenum).
- **Duodenum**
- **Greater duodenal papilla** (medial wall of descending duodenum 8-10cm from pylorus, receives the bile and main pancreatic ducts).
- **Lesser duodenal papilla** (medial wall of descending duodenum 6-8cm from pylorus, contains the opening of the accessory pancreatic duct).
- **Jejunum and ileum**
- **The Mesentery** (double layer of peritoneum which suspends the jejunum and ileum from the posterior abdominal wall).
- **Vascular arcades and vasa recti** (blood vessels within the mesentery).

Lower Digestive System: The Large Intestine

10. The large intestine commences at the ileocaecal junction and terminates at the anus. It is comprised of multiple components which include the caecum and vermiform appendix, ascending, transverse, descending and sigmoid colons, and the rectum and anus. Identify the following features of the dissected specimens:

- **Caecum and vermiform appendix**
- **Ascending, transverse, descending and sigmoid colon.**

- **Right** (hepatic) and **left** (splenic) **flexures**.
- **Taeniae coli** (three longitudinal bands of the outer smooth muscle layer).
- **Appendices epiploicae** (fat-filled appendages of the large bowel, particularly prominent on the transverse and sigmoid colons).
- **Haustrations** (or sacculations, pocket-like bulges of the intestinal wall).
- **Transverse** and **sigmoid mesocolons**.
- **Rectum**
- **Anus**

In barium enema radiographs identify the following features:

- **Haustrations** (sacculations).
- **Caecum**
- **Ascending, transverse** and **descending colon**
- **Sigmoid colon** and **rectum**

On the basis of structure and peritoneal attachments, list features which distinguish: (a) small intestine from colon; (b) transverse colon from sigmoid colon; (c) colon from appendix.

Materials:

- skulls and plastinated head and neck prosected specimens.
- wet head and neck, thorax (deep and mid-sagittally sectioned), abdominal (superficial, deep and posterior wall) and pelvic (superficial and deep) dissections.
- isolated stomachs, livers and pancreases.
- models of the pharynx, abdomen, abdominal organs and pelvis.
- tongue depressors and torches.
- abdominal X-Rays, cholecystograms, barium meal and enema radiographs.

Week 12: Urinary and Reproductive Systems

Learning Objectives

1. To identify and describe the position and posterior relations of the kidneys and the hilum of the kidney and its contents.
2. To identify the renal cortex, medulla, major and minor calices and pelvis of the kidneys in sections of the kidney.
3. To describe the course of the ureters in the abdomen and pelvis.
4. To identify the parts, surfaces, trigone and internal mucosal features of the urinary bladder.
5. To identify the relationships of the male and female urethra and subdivisions and internal features of the male urethra.
6. To identify and describe the components of the urinary system in radiographs.
7. To describe the location and function of the testes and identify its major coverings.
8. To identify the epididymis and understand its function.
9. To describe the origin, course and termination of the ductus deferens.
10. To identify the seminal vesicles, prostate the bulbourethral glands.
11. To identify the attachments and component structures of the penis.
12. To identify the ovaries, uterine tubes, uterus and vagina and their component parts.
13. To identify the peritoneal attachments and immediate visceral relationships of the ovary, uterine tube, uterus and vagina.
14. To know the position of the uterus and identify the components of the female external genitalia (vulva).

Learning Activities

Urinary System: The Kidneys

1. Each kidney extends from the upper border of the 12th thoracic vertebra down to the 3rd lumbar vertebra. The right kidney is situated slightly lower than the left due to the liver. The transpyloric plane (LV1) passes through the superior part of the right hilum and the inferior part of the left hilum. Identify the following features on the kidney models and specimens:
 - **Renal capsule** (line outer covering of kidney).
 - **Renal cortex** and **medulla** (comprised of renal pyramids, papilla, minor & major calices).
 - **Renal pelvis** (region into which the major calices drain).
 - **Ureter** (arises from the base of the renal pelvis).
 - **Renal artery** and **vein**
 - **Renal hilum** (region where renal arteries, veins and ureter enter the kidney)
 - **Renal sinus** (filled with fat tissue).
 - **Right 12th rib** (posterior to right kidney)
 - **Left 11th and 12th ribs** (posterior to left kidney)
 - **Diaphragm, psoas major, quadratus lumborum** and **transversus abdominis muscles** (posterior to both right and left kidneys).

Urinary System: The Ureters, Urinary Bladder and Urethra

2. Each **ureter** arises from the bases of the **renal pelvis** and passes inferiorly along the anterior surface of the **psoas major muscle** and over the **bifurcation of the common iliac arteries**. From here they course around the brim of the **pelvic inlet** and anterior to the **ischial spines** turn medially and attach to the **base of the urinary bladder**.
3. The **urinary bladder** is a pelvic organ which is described as a triangular pyramid. Identify the following features of the urinary bladder:
 - **Base** or **fundus**, **neck** and **apex**
 - **Detrusor muscle** (within the wall of the urinary bladder)
 - **Openings of the ureters** and the **urethra** and the **trigone** (on its internal surface)

4. The **urethra** in female specimens has a relatively short length compared to the male and it is closely related to the pubis and vagina. In males the urethra is divided into several parts. Identify these parts of the urethra in the male specimens and models:
- **Prostatic part** (where it is joined by the ejaculatory ducts)
 - **Membranous part** (where it crosses the pelvic floor)
 - **Spongiose part** (within the penis)

Urinary System: Radiographs and Pyelograms

5. In plain radiographs of the abdomen identify the **kidney shadows** and in intravenous and retrograde pyelograms identify the **minor and major calices, renal pelvis** and the **urinary bladder**.

Male Reproductive System: The Testes, Epididymis and Vas Deferens

6. On the prosected pelvic specimens and isolated **testes** identify the following structures:

- **Tunica vaginalis**
- **Tunica albuginea**
- **Seminiferous tubules** (within the testis)
- **Epididymis head, body and tail**
- **Ductus deferens**
- **Spermatic cord**

7. On the prosected male pelvic specimens and models follow the course of the **ductus deferens** from the **tail of the epididymis**, through the **spermatic cord** to the **inguinal canal** and through the abdominal cavity to the **base of the bladder**. Note the hard cord-like consistency of the ductus deferens compared to vessels in the spermatic cord.

What is the function of the epididymis? What is the best site to cut the ductus deferens during male sterilization?

Male Reproductive System: The Accessory Glands

8. On the prosected male pelvic specimens and models as well as isolated urinary bladder specimens identify the following accessory glands and ducts:

- **Seminal vesicles** (coiled tubular glands)
- **Ampulla of the ductus deferens** (medial to the seminal vesicles)
- **Ejaculatory duct** (formed within the substance of the prostate gland by the junction of the ductus deferens and the duct of the seminal vesicles)
- **Prostate gland** (where the ejaculatory duct joins (empties into) the urethra)
- **Bulbourethral glands**

What are the functions of these structures? What would be the consequences of benign enlargement of the prostate, as commonly occurs in older men?

Male Reproductive System: The Penis

9. The penis is comprised of two main parts: the root and the body. The root is attached to the perineum and comprised of two crura and a bulb. The body or corpus is the free and pendulous part of the penis and is comprised of two corpora cavernosa and a corpus spongiosum. Identify these features in the models and dissected specimens:

- **Crura**
- **Bulb of the penis**
- **Suspensory ligament of the penis** (attaches the body to the symphysis pubis)
- **Corpora cavernosa**
- **Corpus spongiosum** (contains the spongy urethra)
- **Glans of the penis** (dilated end of the corpus spongiosum)
- **Prepuce** (the foreskin of the penis)

What is circumcision?

Female Reproductive System: The Ovaries and the Uterine Tubes

10. The **ovaries** develop high up in the abdominal cavity and migrate down to their final location on the lateral pelvic wall. They are held in position there by several ligaments. Identify the **ovaries** in the prosected specimens and the models of the female reproductive system.
11. The **uterine tubes** are about 10 cm long, and course from of the ovary to the upper lateral margin of the uterus. Identify the following parts of the uterine tube in the specimens and models:
- **Infundibulum** (fimbriated end of the uterine tube - note its relationship to the ovary)
 - **Ampulla**
 - **Isthmus** (narrow region)

Where does fertilisation normally occur? What is an ectopic pregnancy and why might it be dangerous?

Female Reproductive System: The Uterus

12. The **uterus** is located entirely within the pelvis cavity of non-pregnant females and is covered with peritoneum and has a superior or intestinal surface, which is related to the terminal coils of the ileum and a inferior or vesical surface which bends at the isthmus over the superior surface of the urinary bladder. Identify the following components/features and of the uterus:
- **Fundus** (the part of the uterus above the internal openings of the uterine tubes)
 - **Body**
 - **Isthmus** (constricted region about 1cm long at the bottom of the body)
 - **Cervix** (2.5cm long region below the isthmus)
 - **Internal os** (opening between isthmus and cervix)
 - **External os** (opening of the cervix through the anterior wall of the vagina)
 - **Broad ligament** (formed by peritoneum overlying the uterus and uterine tube)

What passes through this cervical opening during life? What are the endometrium, myometrium and perimetrium?

Female Reproductive System: The Vagina and the Vulva

13. The **vagina** is closely related to the urinary bladder (anterior) and the rectum and anus (posterior). Identify the following features:
- **Anterior** (~7.5cm long) and **posterior walls** (~9cm long).
 - **Fornix** (recess around the cervix).
14. The **vulva** is the external genitalia of the female reproductive system. On the specimens and models of the female reproductive system identify the following components of the vulva:
- **Mons pubis** (overlying the pubic symphysis)
 - **Labia majora**
 - **Labia minora**
 - **Clitoris**
 - **Vestibule of the vagina** (contains the external urethral orifice and vaginal orifice)

What medical problems might be caused by the proximity of the urethral and vaginal openings?

Materials:

- kidney and urinary bladder dissections
- deep abdomen prosections
- hip bones and sacrum and superficial and deep pelvic dissections
- isolated male urinary bladder, penis and testes and female uteri
- models of the pelvis and male reproductive system
- X-rays

Week 13: Revision Lab (12-2pm or 2-4pm Tuesday 28/10/2014)

- Note that there will be no lectures in week 13. Revision sessions will be held in the dissection room from 12-2pm and 2-4pm Tuesday 28/10/2014 instead.
- The Revision Lab will cover the material addressed in the practical classes of weeks 9 to 12 (i.e. Cardiovascular system through to the Reproductive Systems).

Week 13: Spot Test No.2 (1-2pm or 2-3pm Wednesday 29/10/2014)

- Note that there will be no practical classes in week 13. Two iterations of Spot test No.1 will be run in the dissection room instead. These will occur during the last hour of the normal Wednesday 11am-2pm class and the first hour of the normal 2-5pm class (i.e. from 1-2pm and 2-3pm).
- Students who normally attend the 11am-2pm practical class are required to attend the 1-2pm test, while those who normally attend the 2-5pm practical class are required to attend the 2-3pm test. A role will be taken at the door of the dissecting room and all students must attend at the time they have been allocated.
- Spot test no.2 will cover the material addressed in the practical classes of weeks 9 to 12 (i.e. Cardiovascular system through to the Reproductive Systems).