THE UNIVERSITY
OF NEW SOUTH
WALES

SCHOOL OF MEDICAL SCIENCES
DEPARTMENT OF ANATOMY

ANAT 3141

Functional Anatomy 2

Session 2, 2011

Class Notes and Lecture Summaries

UNIVERSITY OF NEW SOUTH WALES
SCHOOL OF MEDICAL SCIENCES, DEPARTMENT OF ANATOMY

FUNCTIONAL ANATOMY II - ANAT3141
SESSION 2, 2011

Staff involved in the course:
Course Organiser: Dr Dzung H. Vu, Room 305, Goodsell Building
email: d.vu@unsw.edu.au

Information about the course:
Course relationships: This course covers the musculoskeletal anatomy of the trunk and lower limb. Functional Anatomy I covers musculoskeletal anatomy of the head, neck and upper limb. These courses build on Level II offerings in introductory anatomy and histology, and complement level III courses in neuroanatomy and visceral anatomy.
Course objectives: To provide the student with an understanding of the musculoskeletal anatomy of the trunk and lower limb and the functional principles underlying joint movements in this region.
Teaching strategies: The course is delivered in lecture format complemented by lab classes using prosected specimens and radiographs
Approaches to learning in the course: It is suggested that students attend the lectures and lab classes. Attendance of lab classes are compulsory. Contents of the lectures and class notes are examinable.
NOTE that in the spot test, students should be able to IDENTIFY all anatomical structures listed in the learning activities of the practicals. The written exam will cover all materials presented in the lectures and all questions and discussions listed in the lab classes.
Expected learning outcomes: A student who has completed the course should have a good knowledge of the functional anatomy of the trunk and lower limb, and an understanding of some biomechanical aspects of walking.

Course Structure: There will be two lectures and one lab class per week

Day	Lecture	Lab class
Monday	9-10 Biomed D	10-12:30 pm Dissecting Room
Tuesday	5-6pm Biomed A	
Wednesday		10-12:30 pm Dissecting Room

Assessment in the course
Assessment strategy: Practical aspects of the course will be assessed by two lab-based exams ('spot tests'). Theoretical aspects will be assessed by a final exam incorporating multiple choice and essay components.

Assessment details: Mark allocation is shown below

Continuous assessment	10%
Mid-session Spot Test	20%
Final Spot Test	20%
Final Examination	50%

Assessment dates will be announced but both spot test and written exams will be during exam week. The final examination will consist of 50 multiple choice questions and 3 short answer questions (MCQ's and Questions are worth 50% of the total marks).

Pass mark for the course is 50% but students who achieved less than 42% in one component (either spot test or written exam) will be deemed as having failed the course even if the total mark is 50%. At the discretion of the Course Authority and Assessment committee, further assessment will only be given to some students who are ***borderline*** *(>47%) in the first attempt or who was* ***absent for legitimate reasons****. The date and time for re-assessment will be announced but it will be a few weeks after exam week, as they are not meant for students to study for the course after the first exam. There will be absolutely only* ***ONE re-assessment****, students who do not present for this re-assessment will be given their original fail marks. There will be****NO EXCEPTION****, so please* ***do not book your trips or holidays until the final results are disclosed****.*

About this manual and learning process:

This manual is designed to be a guide for tutors and students and NOT a comprehensive teaching text.
You will be given hand-outs during the lectures, which are not comprehensive teaching text but only guides to help you follow the lectures, to clarify some difficult concept and to give you some emphasis on important issues. Thus they are not posted on the web. Those who miss the lecture can obtain lecture materials from the relevant lab class.
Student's are expected to be prepared for the practical classes by reading textbook and lecture, and they must fully understand all learning activities listed in this manual. Students should bring lecture materials or textbook to the dissecting room to facilitate learning in the lab.

Relevant resources for students enrolled in the course

Textbook details: There is no text that covers all the material in the course. A good textbook of human anatomy will be useful, such as:
MOORE "Clinically Oriented Anatomy" or
SNELL, R.S. "Clinical Anatomy for Medical Students"

Recommended:
YOKOCHI, ROHEN & WEINREB "Photographic Anatomy of the Human Body" or
ROHEN ,YOKOCHI & LUTJEN-DRECOLL "Color Atlas of Anatomy"

Administrative matters

Official communications: All students in course ANAT3131/3531 are advised that email is now the official means by which the School of Medical Sciences at UNSW will communicate with you.
Occupational Health and Safety: For full details, refer to the Faculty of Medicine URL: http://ohs.med.unsw.edu.au/
You must wear laboratory coat and closed shoes in the laboratory and bring gloves to all lab classes TO HANDLE WET AND DRY SPECIMENS DURING TUTORIAL/LAB CLASSES.
Applications for Consideration. Students who miss an assessment through illness or misadventure must submit an application for consideration within three working days to Student Central. Request for special consideration is available at https://my.unsw.edu.au/student/atoz/consideration.pdf
Grievance:
See https://my.unsw.edu.au/student/atoz/Complaints.html
Attendance. Students are required to attend **each lecture & laboratory class** unless given special permission. Provision of an appropriate medical certificate will be required for Special Consideration.

Rules of use of the Dissecting Room

You may enter and view specimens in the Dissecting Room 101 only in the presence of your tutor and/or during your designated laboratory class hours. You are not allowed to take visitors into the Dissection Room.

In the Dissecting Room, you must: **never eat** or **drink**; never put anything in your **mouth**, e.g., biros or pencils that you may have picked up from the table; wear a laboratory **coat**; wear covered **shoes**, not thongs; wear latex or vinyl **gloves** when touching wet specimens (gloves are available from Union Arcade Shop); use blunt **forceps** only to handle specimens and **probes** to point to structures, and **never pull** at any parts of the specimen; as far as possible, **avoid inhaling** preservative solutions for prolonged periods (if you feel in need of fresh air, ask permission to leave the laboratory for a few minutes); and at the end of your laboratory: **cover wet specimens** with the towels provided; **replace stools** under the tables in your cubicle; **wash your hands** and instruments.

Great **care** should always be exercised when handling specimens, in order to preserve their delicate structure. Much work has gone into the **prosection** of each specimen before it is ready for use in class. A damaged specimen cannot be replaced immediately, so it will not be available to students for a long time.

You are learning from human material prepared from people who have generously donated their bodies for the benefit of science. Apart from caring for the specimens, it is important for all students learning Anatomy to have and show **utmost respect** for the specimens at all times, in the Dissecting Room and in the Anatomy Museum. It is **illegal** for any anatomical material to be removed from the premises of the Department of Anatomy for any purpose whatsoever (except of course, for the funeral).

Preservative solution. Most anatomy specimens are stored in 2% phenoxyethanol, which is classified as non-toxic. You should always wear gloves when handling specimens. Detailed information about phenoxyenthanol is posted on the Dissecting Room notice board. A few specimens (brain tissue, etc.) are stored in formaldehyde, which is toxic if ingested, and corrosive to the eye; it can also be absorbed through the skin. Formaldehyde is reported to cause allergic skin and respiratory effects. The potential for adverse health effects, however, is markedly reduced at the concentrations used for embalming and storage of specimens in the Dissecting Room. Moreover, the air in the Dissecting room is continuously changed and specimens are not stored in formalin anymore. Essentially, you should prevent any preservative solution from coming in direct contact with your eyes, skin or mouth. **First Aid kit is available in the dissecting room**.

All anatomy specimens are microchipped for identification and record-keeping.

Revision Facilities are available in the Anatomy Museum (normally open 9 am - 5 pm, Monday to Friday). Please do not remove the museum jars from their shelves.

Photography and video recording is **not permitted** in the Dissecting Room or the Anatomy Museum.

COURSE SCHEDULE 2008
FUNCTIONAL ANATOMY II (ANAT 3141)

Wk	Date	Lecture	Lab class
2	Mon 25 Jul	AXIAL SKELETON	Vertebral column
	Tue 26 Jul	PARAVERTEBRAL MM	Vertebral column
3	Mon 01 Aug	ABDOMINAL MM	Muscles of back and neck
	Tue 02 Aug	INGUINAL REGION HERNIA	Muscles of back and neck
4	Mon 08 Aug	HIP JOINT	Abdominal mm, inguinal region
	Tue 09 Aug	MUSCLES OF THE THIGH	WED: Abdominal mm, inguinal region
5	Mon 15 Aug	KNEE JOINT	Hip joint and associated anatomy
	Tue 16 Aug	BONES OF THE LEG & FOOT	WED: Hip joint and assoc. anatomy
6	Mon 22 Aug	MUSCLES OF THE LEG	Femur and thigh muscles
	Tue 23 Aug	ANKLE JOINT 1	WED: Femur and thigh muscles
7	Mon 29 Aug	ANKLE JOINT 2	REVISION CLASS
	Tue 30 Aug	***MID-SESSION SPOT TEST (5 – 6pm)***	WED: REVISION CLASS
		RECESS 03 Sep to 11 Sept	
8	Mon 12 Sep	FOOT	Knee and associated anatomy
	Tue 13 Sep	LUMBOSACRAL PLEXUS	WED: Knee and associated anatomy
9	Mon 19 Sep	NERVES OF THE LOWER LIMB	Ankle & Foot 1
	Tue 20 Sep	IV DISC	WED: Ankle & Foot 1
10	Mon 26 Sep	NERVE ROOT LESIONS	Foot 2 – Lumbosacral Plexus
	Tue 27 Sep	VESSELS OF LOWER LIMB 1	WED: Foot 2 – Lumbosacral Plexus
11	Mon 03 Oct	VESSELS OF LOWER LIMB 2	Nerves & Vx of lower limb
	Tue 04 Oct	SECTIONAL ANATOMY	WED: Nerves & Vx of lower limb
12	Mon 10 Oct	RADIOLOGICAL ANATOMY	Surface anatomy & REVISION
	Tue 11 Oct	REVIEW: NERVES	WED: Surface anatomy & REVISION
13	Mon 17 Oct	REVIEW: VESSELS	NO LAB
	Tue 18 Oct	EXAM TECHNIQUES	NO LAB

SPOT TEST (To be announced later)

Study period - 22 Oct to 27 Oct
Examinations - 28 Oct to 15 Nov

LAB CLASS 1: VERTEBRAL COLUMN

LEARNING ACTIVITIES:

1. Spinal curvatures: Observe an articulated vertebral column. Note the normal curvatures of the spinal column in the sagittal plane and identify the primary and secondary curvatures. What is lordosis, kyphosis and scoliosis?

2. Note that the inclination of the spinous processes (SP) increases from the cervical to the thoracic region then is much less in the lumbar region. The spinous process of L4 is at the level with the highest point of the iliac crest, and the spinous process of S2 is level with a line joining the PSIS's.

3. On a mid-thoracic vertebra, identify the main parts of a typical vertebra: body, pedicle, lamina, transverse process, spinous process, superior and inferior articular processes, vertebral notch. Put 2 vertebrae together and see what structures form the zygapophyseal joint (facet joint), and what structures make up the intervertebral foramen. Observe the change in the orientation of the facet joint in the cervical, thoracic and lumbar vertebrae.

4. Note the features of a **mid-cervical vertebra** and label the following features on the diagrams below: body (rectangular in shape), uncinate process, anterior and posterior tubercles of transverse process, foramen transversarium, vertebral foramen (large, triangular), articular process, spinous process (bifid). Note that the articular facet joint surface is flat and inclined. What is uncovertebral joint (of Luschka)? What movement is possible between the typical cervical vertebrae and why? What is *vertebra prominens*?

5. **Features of C1 vertebra (Atlas)**: lateral mass with tubercle for transverse ligament, anterior arch with articular surface for the dens, posterior arch. Find the superior aspect of the bone which has concave articular surfaces and grooves for vertebral artery. On the articulated vertebral column, note that the transverse process of C1 is longest of all TPs? Why?

6. **Features of C2 vertebra (Axis)**: odontoid process (or dens) which has an articular surfaces for the anterior arch of C1 and a notch for transverse ligament

7. **Feature of thoracic vertebra**: body which has two demifacet for the heads of the ribs (except for T9 to T12), transverse process (club-shaped) with facet for the tubercle of corresponding rib (except for T11-T12) Put two thoracic vertebrae together, see how the facet joints are oriented and which movement would be facilitated by this orientation.

8. Put a rib against a thoracic vertebra: note how the rib articulates with the body (costovertebral joint) and with transverse process (costotransverse joint)

9. **Features of lumbar vertebra**: body (large, kidney-shaped), transverse process with accessory process, short spinous process. Note direction of the articular processes and their facet joint, and the mamillary process on the superior articular process. What movement would be difficult with the orientation of the facet joints? What is *pars interarticularis* and could result from fracture at that point?

10. **Features of the sacrum**.
On the anterior surface of the sacrum, identify the transverse lines separating the five original segments, ala, sacral promontory, the pelvic sacral foramina. What goes through the pelvic sacral foramen? Draw on the diagram the area of attachment of the muscle piriformis.
On the posterior surface of the sacrum, identify the articular facet, sacral hiatus, cornua. What go through the dorsal sacral foramina? Identify the median, intermediate and lateral sacral crests. What homologous parts of a typical vertebra do they represent?
On the lateral side, identify and state the function of auricular surface and sacral tuberosity.
Where is the sacral canal and what does it contain?
Note the sacrovertebral angle between the scarum and lumbar column on the articulated spinal column.

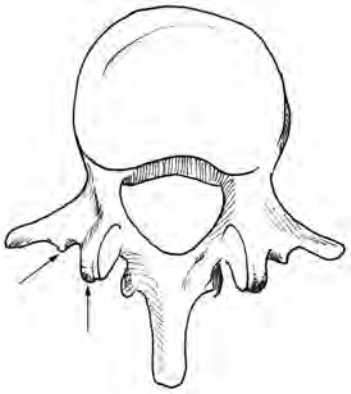

11. **Features of the coccyx**: it has rudimentary cornua and no vertebral canal, pedicle and spinous process.
12. X-rays: identify all the above features on X-rays of vertebral column

SUMMARY

	CERVICAL	THORACIC	LUMBAR
Size	small	medium	large
Spinous process	short,bifid	long	thick,oblong plate
Superior articular processes	face back and up	face back & lat.	face back & medial
Movements allowed	Flex/extension, lateral flexion	rotation, lateral flexion to one side accompanied by rotation to same side	flex/extension
Other	Transverse processes perforated (foramen transversarium)	costal facet (for head of rib), tranverse facet	mammillary process on superior zygapophysis

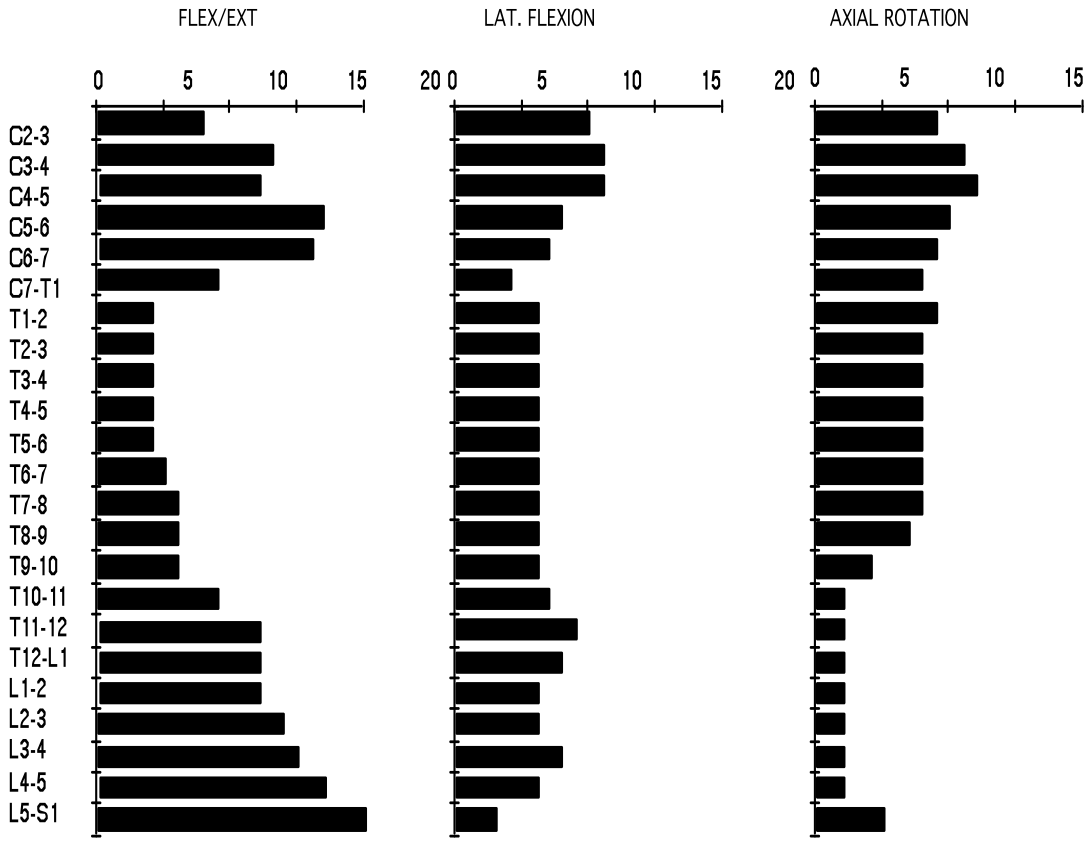

Chart after White & Panjabi (1978) 'Clinical Biomechanics of the Spine'.

Materials: Vertebrae, articulated spinal columns, specimens showing vertebral ligaments, radiographs.

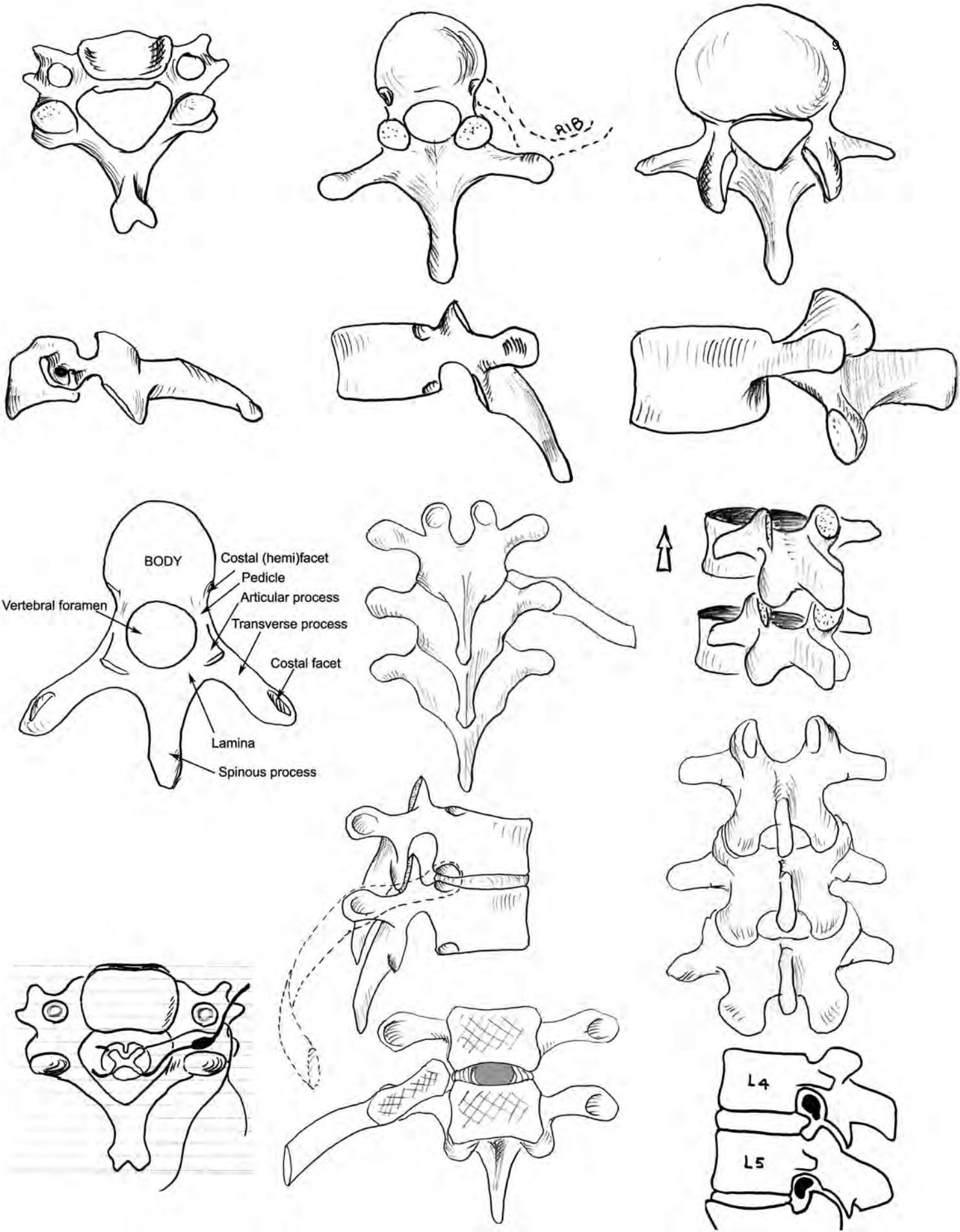
RIB
BODY
Costal (hemi)facet
Pedicle
Articular process
Vertebral foramen
Transverse process
Costal facet
Lamina
Spinous process
L4
L5

VERTEBRAL COLUMN (SPINAL COLUMN)

Primary curvatures: concave forward, in utero. Due to shape of the bodies
Secondary curvatures: convex forward. Due to shape of IV discs

- Cervical curve (3rd – 4th month) to hold head upright
- Lumbar curve (about 12th – 18th month) to stand and walk

Curves dissipate and absorb compression forces
Exaggeration of primary curvature is kyphosis, of secondary curvature is lordosis
Scoliosis: curve in the coronal plane
REGIONS: 7 cervical, 12 thoracic, 5 lumbar, sacrum (5 fused "sacrabrae"), 4 coccygeal)

MOVEMENTS OF THE VERTEBRAL COLUMN

Flexion – Extension - Lateral flexion/bending - Rotation

PARTS OF A TYPICAL VERTEBRA

Body
Pedicles
Superior and inferior vertebral notches – They contribute to intervertebral foramen
Lamina
Transverse process (TP)
Articular process (AP)
Articular facet – facet joint (zygapophyseal joint)
Spinous process (SP)
Inclination varies with the vertebral segments
ertebral foramen. Vertebral canal

REGIONAL SPECIALISATION

	CERVICAL	THORACIC	LUMBAR
Body			
Vertebral foramen			
Pedicle			
Articular facet			
Transverse process			
Lamina			
Spinous process			
Movements			

ATYPICAL VERTEBRAE

SACRUM
Pelvic surface: pelvic sacral foramina
Dorsal surface: dorsal sacral foramina, median, medial and lateral foramina (homology?)
Body, promontory, ala
Sacral canal, sacral hiatus, Cornua

COCCYX

ATLAS (C1)
Lateral masses (transverse ligament)
Anterior arch (articular facet for dens), posterior arch. Long transverse process, groove for vertebral art.

AXIS (C2): dens (odontoid process

VERTEBRA PROMINENS (C7)

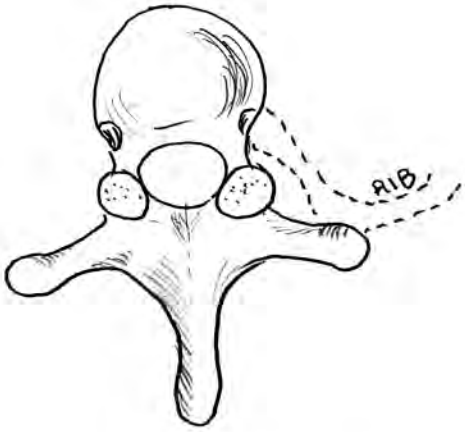

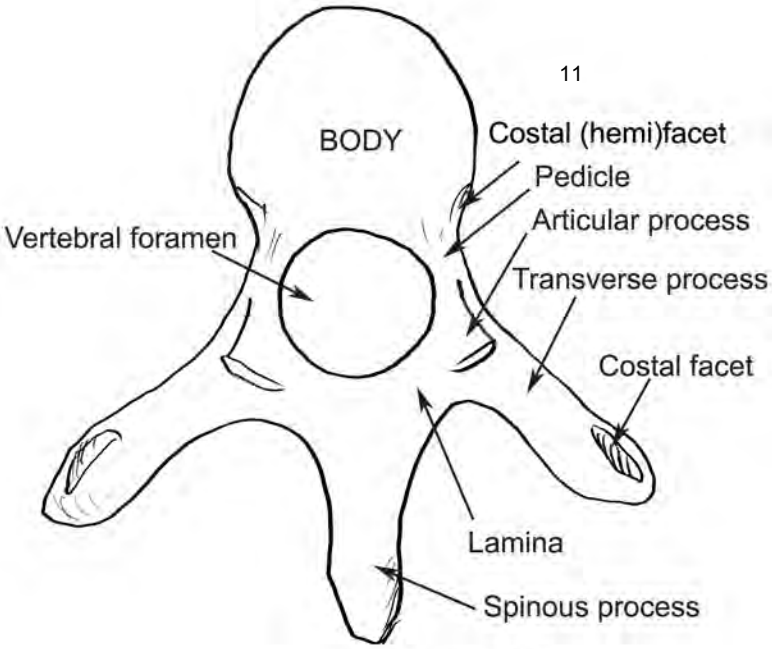

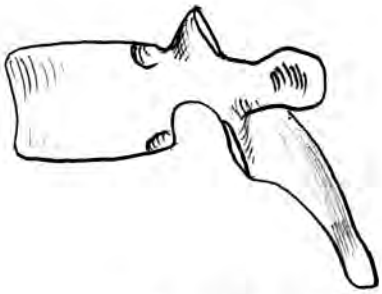

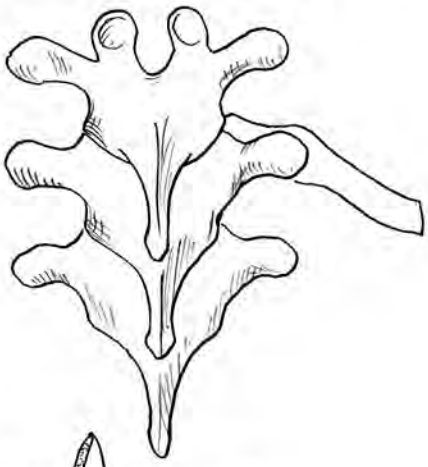

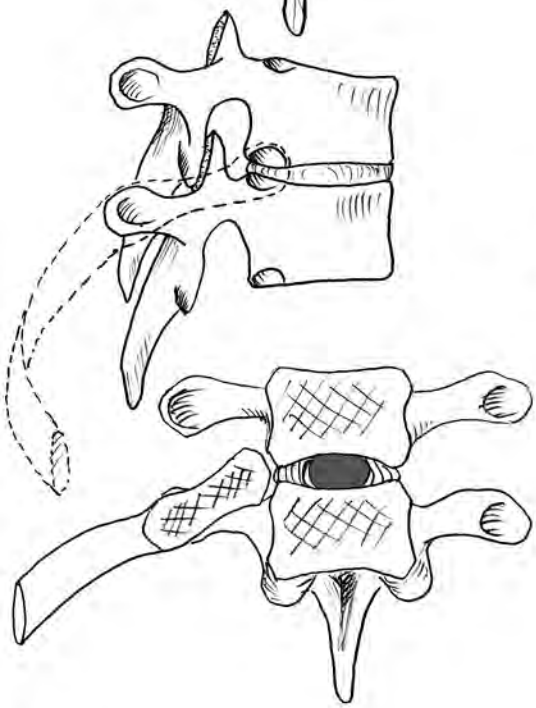

LIGAMENTS:
1. Radiate
2. Costotransvese
3. Lateral costotransverse
4. Superior costotransverse

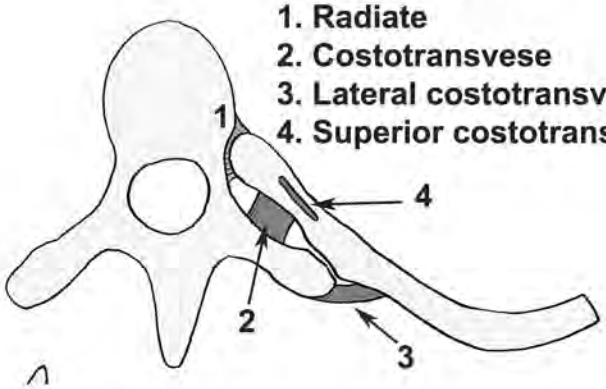

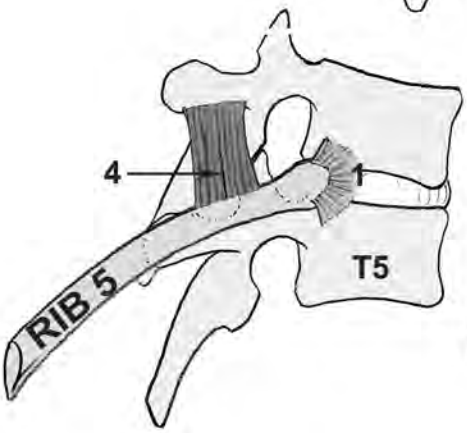

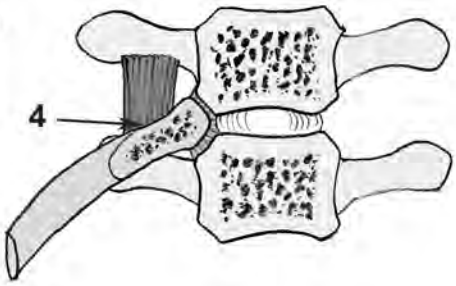

Lumbar vertebrae

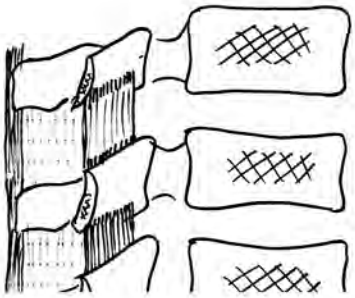

JOINTS OF THE VERTEBRAL BODIES

ANT LONG LIG
POST LONG LIG upper end continuous with membrana tectoria.
INTERVERTEBRAL DISCS 1/5 of the total length of the vert. column, thicker in C & L

JOINTS OF VERTEBRAL ARCHES

ARTICULAR CAPSULE:	Thin & loose, attached to margins of articular facet.
LIGAMENTUM FLAVUM:	between laminae,
SUPRASPINOUS LIG:	Connect apices of SP's (in series with Lig nuchae)
INTERSPINOUS LIG:	between SP's
INTERTRANSVERSE LIG	

MOVEMENTS OF THE VERTEBRAL COLUMN

FLEXION	most extensive in C & L
EXTENSION	Free in C & L, restricted in T
LAT FLEXION	Always associated with some rotation. Most free in C & L
CIRCUMDUCTION limited	
ROTATION	freer in upper T, least in L

ARTICULAR FACETS

CERVICAL:	Upward inclination allows free flex & ext.
THORACIC:	Rotation is freer (Art. facets correspond to the surface of a cylinder with the centre near the centre of vertebral body) but all mvts are limited (because of ribs & sternum)
LUMBAR:	Extension free & wider in range than flexion Rotation limited by the direction of articular facets

CRANIOVERTEBRAL JOINTS

LATERAL ATLANTO-AXIAL JOINTS
Fibrous capsule: thin & loose

MEDIAN ATLANTO-AXIAL JOINT: Pivot joint.
TRANSVERSE LIG OF C1
+ longitudinal bands = cruciform lig of the atlas.
ACCESSORY ATLANTOAXIAL Lig: Near the base of dens to C1 and Occipital bone (near XII canal)

MOVEMENT AT THE ATLANTO-AXIAL JOINTS
rotation of C1 upon C2, extent being limited by alar and accessory atlantoaxial ligaments

ATLANTO-OCCIPITAL JOINTS
Ellipsoid. Articular surfaces can be considered as part of the surface of a sphere
Fibrous capsules
ANT ATL-OCC MEMBR. Ant arch of CI to margin of foramen magnum
POST ATL-OCC MEMBRANE Post arch of CI to margin of foramen magnum

MOVEMENTS AT ATL-OCC JOINTS Flex & ext, slight lateral tilting

LIGTS CONNNECTING AXIS WITH OCCIPITAL BONE

MEMBRANA TECTORIA	upwards extension of post long lig, blends with cranial dura
ALAR LIGAMENTS	dens to medial side of occipital condyles
APICAL LIG OF THE DENS	apex of dens to margin of foramen magnum
ACCESSORY ATLANTOAXIAL Lig:	Near the base of dens to C1 and Occipital bone (near XII canal)
LIGAMENTUM NUCHAE	

JOINTS OF VERTEBRAE & RIBS

COSTOVERTEBRAL JOINT:	Vertebral bodies with head of rib Ligaments: radiate & interarticular
COSTOTRANSVERSE JOINT:	TP & rib Ligaments: costotransverse, lateral costotransverse, superior costotrransverse

LAB CLASS 2: LIGAMENTS & MUSCLES OF NECK & BACK

LEARNING ACTIVITIES:

LIGAMENTS OF THE VERTEBRAL COLUMN

1. On the diagram below, draw the position of the following ligaments: anterior longitudinal, posterior longitudinal, supraspinous, interspinous, intertransverse, ligamentum flavum. The ligamentum nuchae is a fibroelastic membrane stretching from the external occipital crest to the spinous processes of all cervical vertebrae, it is homologous to the supraspinous and interspinous ligaments elsewhere.

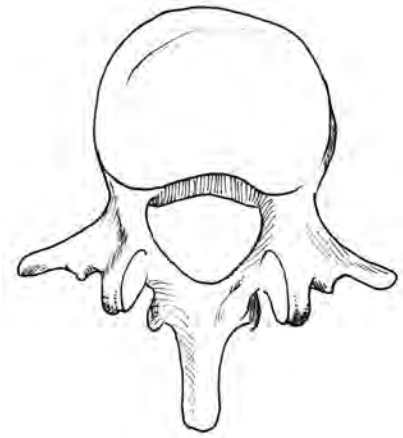

2. On the specimens, compare the anterior longitudinal ligament (ALL) and posterior longitudinal ligament (PLL). Note that the PLL is much wider over the intervertebral disc than over the body than the ALL and that the PLL is separated from the middle portion of the body by the basivertebral vein.

3. Look for a specimen which shows the section of an intervertebral disc. Identify the annulus fibrosus and possibly the area of the nucleus pulposus. In the specimens of old subject, the demarcation between the annulus and nucleus pulposus is not easily discernible.

CRANIOCERVICAL LIGAMENTS

4. The anterior atlanto-occipital membrane connects the anterior arch of C1 to the anterior margin of foramen magnum, the posterior atlanto-occipital membrane connects the posterior arch of C1 to the remainder of the foramen magnum (These membranes are removed in our specimens). The following ligaments and membrane are best seen in the museum specimen.
5. From the dens (C2) to occipital bone: apical ligament of the dens (apex of the dens to foramen magnum), alar ligaments (from posterolateral surface of the dens to medial surface of occipital condyles). Accessory atlantoaxial ligament (from the dens near attachjment of apical ligament
6. Cruciform ligament: transverse ligament and superior and inferior longitudinal bands (to clivus and body of C2 respectively)
7. Membrana tectoria is the upward continuation of anterior longitudinal ligament to clivus

MUSCLES OF THE BACK

8. Interspinales and intertransversarii: small muscles between SP's and TP's, not present throughout the vertebral column, not visible on our prosected specimens. Function: mostly stabilisation of the volumn during movement

9. TRANSVERSOSPINALIS: deep layer of intrinsic Mm of the back, lies in the groove between SP's and TP's. From deep to superficial are:
   - Rotatores: span 1-2 segments. Best developed in thoracic region
   - Multifidus: from each SP, multiple bundles span 1-4 segments to TP's below. Best developed in lumbar region
   - Semispinalis: span 8-10 segments. Only exists in the thorax and neck region, has 3 parts thoracis, cervicis and capitis

10. ERECTOR SPINAE or SACROSPINALIS: superficial layer of the intrinsic mm
From a broad tendon attached to the sacrum, lumbar spines and iliac crest, it splits into 3 columns. Iliocostalis is the most lateral, Longissimus is the largest & longest, Spinalis the most medial. *Spinalis is variable, blends with semispinalis and you do not need to identify it.*

	SPINALIS	LONGISSIMUS	ILIOCOSTALIS
Insertion:	Thoracis	Thoracis (thoracic TPs + ribs)	Lumborum (lower 6 ribs)
Insertion:	Cervicis	Cervicis (TPs of T4-C2)	Thoracis (upper 6 ribs)
Insertion:	Capitis	Capitis (mastoid process)	Cervicis (TPs of C4-6)

11. Identify the thoracolumbar fascia which covers the intrinsic Mm of the vertebral column and continues anteriorly into the aponeuroses of internal oblique and transversus abdominis.

MUSCLES OF THE NECK

12. Identify the splenius cervicis and splenius capitis. Note that semispinalis capitis is visible in the gap formed between the two splenius capitis

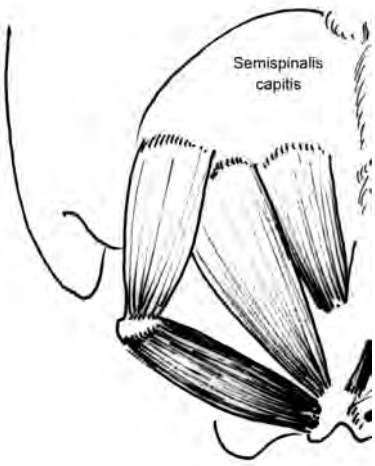

12. Identify four SUBOCCIPITAL MUSCLES
- Rectus capitis posterior minor
- Rectus capitis posterior major
- Obliquus capitis inferior
- Obliquus capitis superior

All the suboccipital mm. are innervated by the dorsal ramus of C1 (suboccipital nerve). The last three form the borders of the suboccipital triangle.

13. PREVERTEBRAL MUSCLES
- *Longus colli*
- *Longus capitis*
- *Rectus capitis anterior* lateral mass of C1 to front of occipital condyle
- *Rectus capitis lateralis:* transverse process of C1 to region lateral to occipital condyle

All four are innervated by anterior rami of cervical nerves; the last two can only be seen on one or two specimens.

Identify the vertebral angle between the longus colli and scalenus anterior where the vertebral artery is seen to enter the foramen transversarium of C6

14. Identify the two major triangles of the neck separated by the SCM: anterior and posterior cervical triangles
Note that the floor of the posterior triangle is formed by splenius capitis, levator scapulae, and scalenus medius and posterior. Important contents are the spinal accessory nerve, the trunks of the brachial plexus, and the subclavian a.

Materials: Vertebrae, ribs, neck prosections, deep thoraxes for longus colli and capitis, prosected back specimens.

LECTURE: PARAVERTEBRAL MUSCLES

LIGAMENTUM NUCHAE: interspinous = supraspinous ligaments. Attached to external occipital crest

THORACOLUMBAR FASCIA: trilaminar in the lumbar region, covers quadratus lumborum (i) and erector spinae (ii), from TP (iii)

INTRINSIC MUSCLES OF THE BACK:

TRANSVERSOSPINALIS (between TPs and SPs)

- Rotators: span 1-2 vertebrae
- Multifidus: spans 1-4 vertebrae
- Semispinalis: spans 8-10 vertebrae
  - S. thoracis
  - S. cervicis: reaches C2
  - S. capitis: reaches occipital bone, between superior and inferior nuchal lines (covered by trapezius)

ERECTOR SPINAE

From a broad tendon which is attached to sacrum, lumbar spines and iliac crest.
Splits into three columns, each can be described in three sections:

- Spinalis (Cannot be differentiate from semispinalis)
- Longissimus: L. thoracis, cervicis and capitis
- Iliocostalis: . lumborum, thoracis and cervicis

Iliocostalis:

- *lumborum*: from sacrum to angles of lower 6 ribs
- *thoracis*: lower 6 ribs to upper ribs
- *cervicis*: ribs 3-6 to TPs of C4-C6

Longissimus:

- *thoracis*: from sacrum to TPs of all thoracic vertebrae and lower 10 ribs
- *cervicis*: TPs of upper 4 Thoracic vertebrae to TPs of lower 4 cervical vertebrae
- *capitis*: FROM TPs of upper 4 Thoracic vertebrae, AP of lower 4 cervical vertebrae TO mastoid process

IN THE NECK

SUBOCCIPITAL MUSCLES

- *Rectus capitis posterior minor:* posterior tubercle of C1 to below inf nuchal line.
- *Rectus capitis posterior major*: spine of C2 to below inferior nuchal line.
- *Obliquus capitis inferior*: spine of C2 to TP of atlas
- *Obliquus capitis superior:* TP of C1 to above the inferior nuchal line.

SPLENIUS

- S. cervicis: SP of T3-T6 to TPs of C1-C3
- S. capitis: Lig nuchae and SP of T1-T3 to below superior nuchal line

PREVERTEBRAL MUSCLES

- *Longus colli:* bodies of T1-T3 to TPs of C3-C6 and to bodies of C2
- *Longus capitis:* TPs of C3-C6 to basilar part of occipital.
- *Rectus capitis anterior:* lateral mass of C1 to front of occipital condyle
- *Rectus capitis lateralis:* TP of C1 to lateral to occipital condylle

LAB CLASS 3: ABDOMINAL MUSCLES & INGUINAL REGION

LEARNING ACTIVITIES

1 On the hip bone, identify the iliac crest, anterior superior iliac spine (ASIS), pubic crest, pubic tubercle, pecten pubis. On the articulated skeleton, identify the pubic symphysis, the sternum, costal cartilages of the first 10 ribs. Note that ribs 11 and 12 are floating ribs.

POSTERIOR ABDOMINAL WALL

2. Identify the muscles of the posterior abdominal wall: psoas major, psoas minor (if present) and quadratus lumborum and the iliolumbar ligament.
   Follow the psoas tendon until its femoral attachment on lesser trochanter together with iliacus tendon.
   Identify the genitofemoral nerve which penetrates the psoas major, the femoral nerve and obturator nerve on the lateral and medial sides of the lower part of the psoas

ANTEROLATERAL MUSCLES OF THE ABDOMINAL WALL

3. *External oblique*: note that its muscle fibres are attached to the lower 8 ribs and anterior half of iliac crest and end in the external oblique aponeurosis. What is the direction of the muscle fibres? Follow the external oblique aponeurosis, it joins the contralateral aponeurosis at the midline (linea alba), its lateral border runs roughly vertical from 9th costal cartilage to the level of the umbilicus then veers towards the ASIS, its lower border running from ASIS to pubic tubercle is free and called inguinal ligament.
   Turn to the back of the specimen to identify the posterior b order of the muscle which is free and not attached to thoracolumbar fascia.
4. *Internal oblique*: Look for its posterior attachment on the thoracolumbar fascia in the back, together with transversus abdominis. The muscle fibres are attached to the anterior 2/3 of the iliac crest and lateral third of inguinal ligament. The upper fibres run upwards toward the midline, the lower fibres become fibrous and arch over spermatic cord to attach to pecten pubis and pubic crest.
5. *Transversus abdominis:* fibres run horizontally and forwards from the thoracolumbar fascia, the anterior 2/3 of the iliac crest, lateral 2/3 of inguinal ligament, and the lower 6 costal cartilages. Look for conjoint tendon where the aponeuroses of internal oblique and transversus abdominis join at the edge of rectus
6. *Rectus abdominis:* from xiphoid process to pubic crest. Identify the linea semilunaris, linea alba, and tendinous intersections on its anterior surface. Identify the rectus sheath, note that it is deficient posteriorly below the arcuate line. What form the rectus sheath. What form the linea alba? Of the arteries which run posterior to rectus abdominis in the rectus sheath, you can easily identify the inferior epigastric artery. Where does it originate?
7. Discuss with your tutor the actions of the anterolateral abdominal muscles. Why do they flex the vertebral column, increase intraabdominal pressure and rotate the trunk by working in pairs?
8. Discuss the action of rectus abdominis.

INGUINAL CANAL

9. On the anterior surface of the specimen of anterior abdominal wall, identify the inguinal ligament, superficial inguinal ring (a gap in the external oblique aponeurosis), spermatic cord as it ascend from the testis to enter the superficial inguinal ring
10. What is fascia transversalis? (It has been removed in our prosected specimens)
11. Turn to the posterior surface of the specimen, identify the inguinal ligament, conjoint tendon, aponeurosis of transversus abdominis, deep inguinal ring which is lateral to the inferior epigastric artery (See diagrams next page). The inguinal canal zigzags between the superficial and deep inguinal rings and contains spermatic cord in the male and round ligament in the female. If the group has a specimen with intact vas deferens, follow it through the inguinal canal to the back of the bladder and note its relation with the inferior epigastric artery.

12. **Indirect** inguinal hernia is the protrusion of abdominal contents (usually bowels) through the inguinal canal. **Direct** inguinal hernia is the protrusion at the of Hesselbach's triangle (see diagram next page). The landmark separating the 2 types of hernia is the inferior epigastric artery, hence the importance of this artery for the differentiation of direct and indirect inguinal hernia in surgery

Materials: Pelvis, sacrum, coccyx, models, prosected specimens showing muscles of abdomen, sacrospinous and sacrotuberous ligg., X-rays

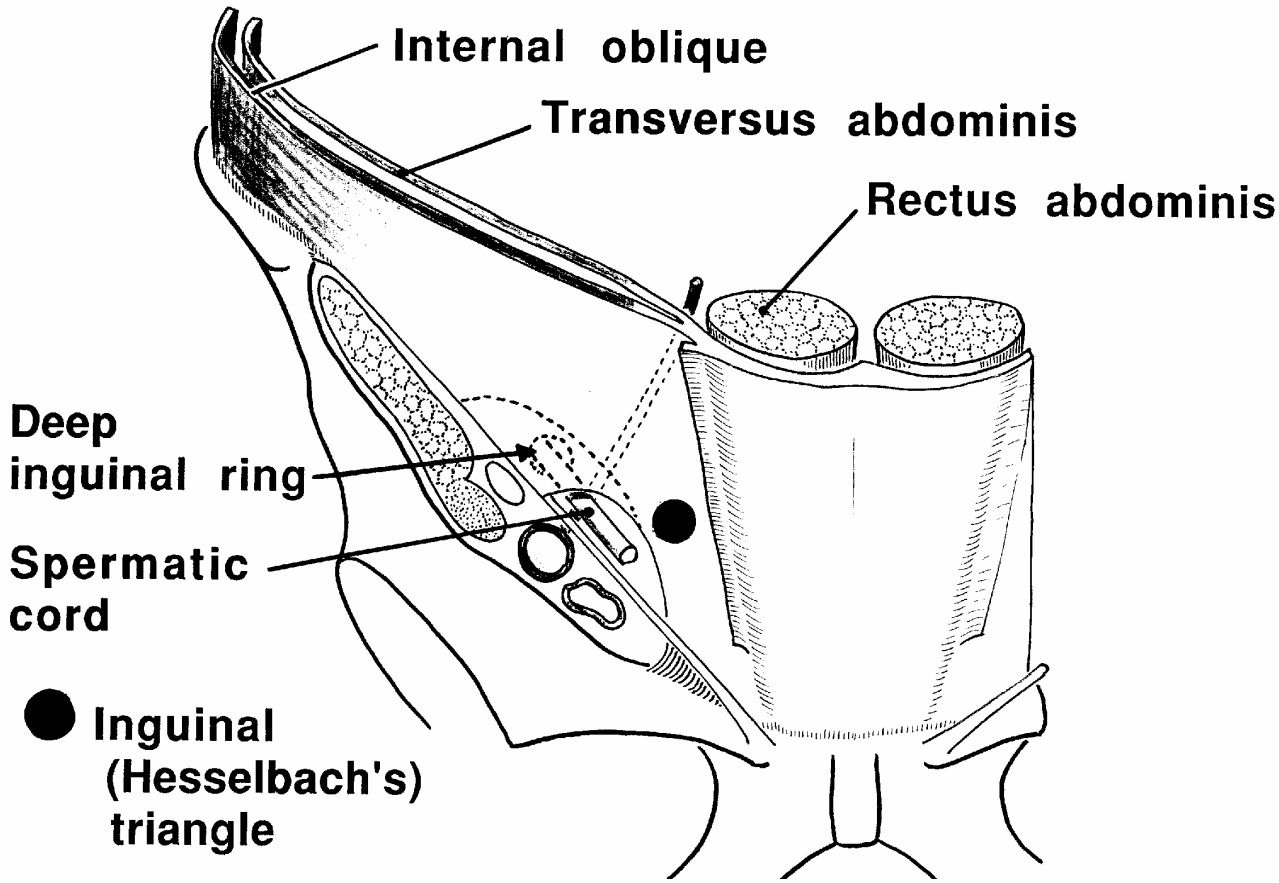

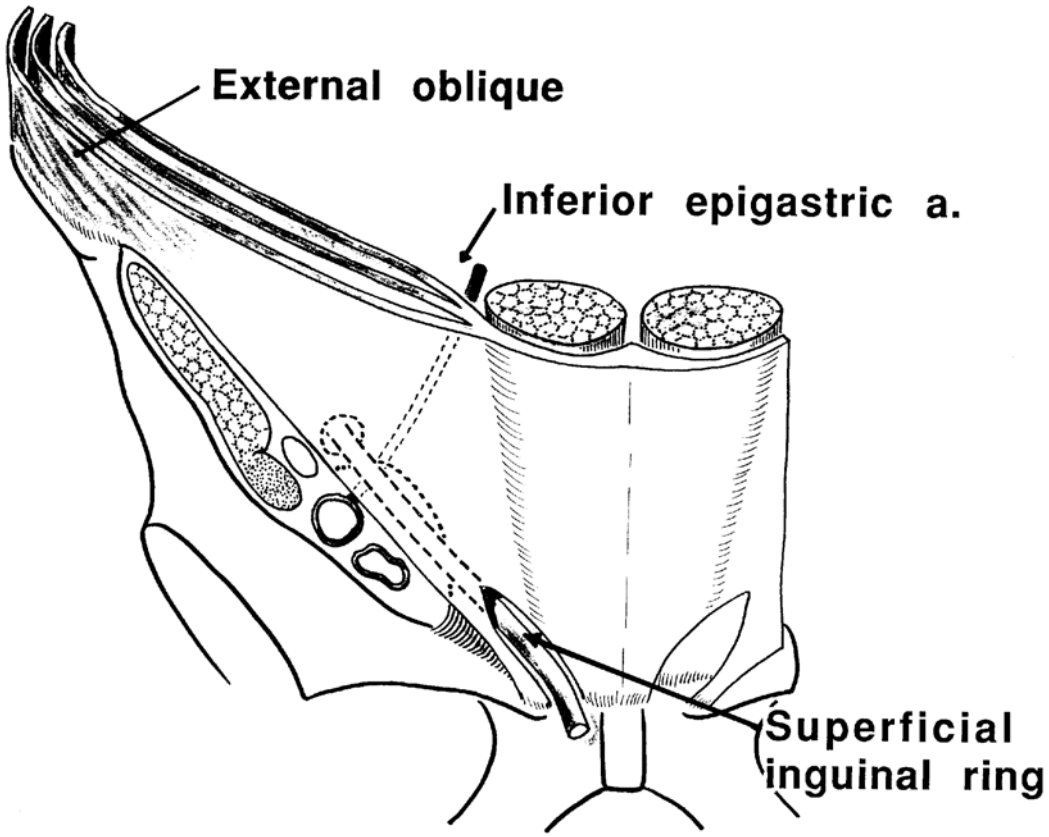

LECTURE : MUSCLES OF THE ABDOMEN

POSTERIOR ABDOMINAL WALL:
- Psoas, Quadratus lumborum

ANTEROLATERAL GROUP:
- External oblique, internal oblique, Transversus abdominis
- External oblique aponeurosis: superficial inguinal ring, inguinal ligament
- Conjoint tendon
- Formation of rectus sheath, arcuate line. Linea alba

ANTERIOR GROUP: Rectus abdominis

ACTIONS
- "Compress" abdo viscera & assists in expelling air during expiration
- Flex vertebral column, laterally flex trunk (unilateral contraction)
- Rotate trunk (Ext Oblique + contralateral Int Oblique)

Abdominal Muscles

	Origin	Insertion	Special features
Obliquus externus abdominis	5th–12th rib (interdigitating with the ant. serratus)	Outer lip of the iliac crest, inguinal lig., linea alba, pubic tubercle	Forms the muscular corners visible on each side of the lower abdomen
Obliquus internus abdominis	Thoracolumbar fascia or aponeurosis, intermediate line of the iliac crest, inguinal lig.	9th–12th rib, linea alba	Principal origin of the cremaster muscle
Transversus abdominis	Inner surface of 7th–12th ribs, thoraco-lumbar fascia, inner lip of the iliac crest	Linea alba	Ventral margin forms the semilunar line
Rectus abdominis	5th–7th rib, xiphoid process of the sternum	Pubis	Post. rectus sheath forms the arcuate line (of Douglas) half way between navel and symphysis pubis

LECTURE : INGUINAL HERNIA
(next page)

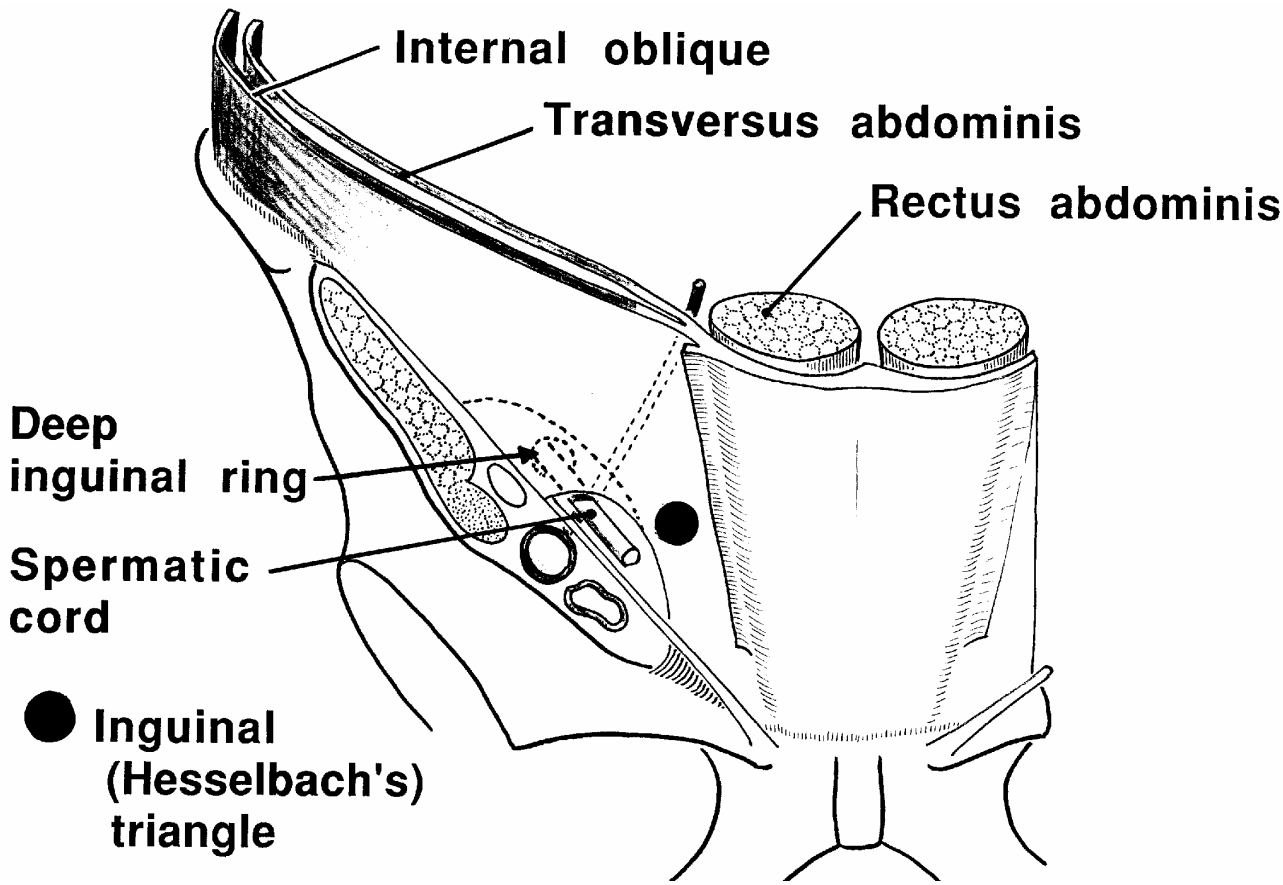
Internal oblique
Transversus abdominis
Rectus abdominis
Deep inguinal ring
Spermatic cord
Inguinal (Hesselbach's) triangle

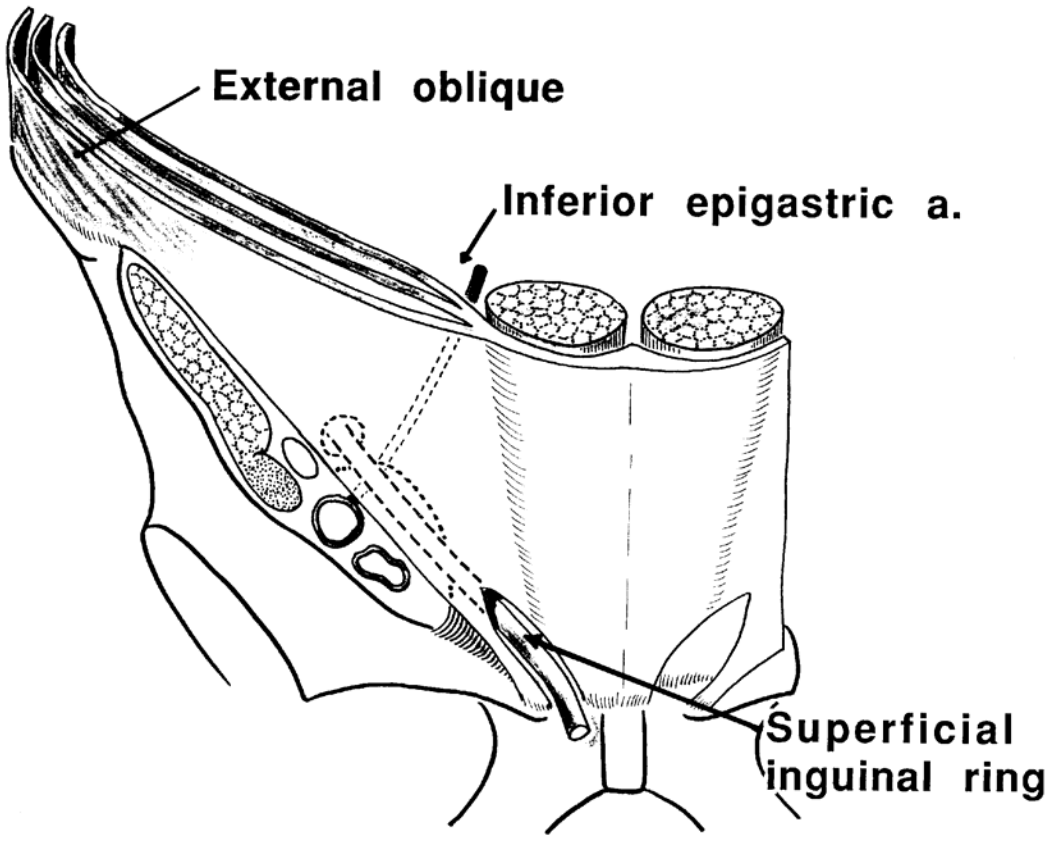
External oblique
Inferior epigastric a.
Superficial inguinal ring

D.Vu 96

INGUINAL LIG (Poupart's lig, crural or superf crural arch):
- inrolled border of ext obliq aponeurosis (forming the floor of inguinal canal)
- from ASIS to pubic tubercle, 12-14cm long, 40-35 degrees to horizontal, medial part horizontal to support sperm cord

LACUNAR LIG (of Gimbernat)
- Extends posterolat from medially part of inguinal lig to medial end of pecten pubis.
- Triangular, almost horizontal (seen better from above from its abdominal aspect, not from the front as in the anatomical drawings!)Its post margin continuous with pectineal fascia
-

PECTINEAL LIG (of Astley Cooper) extends laterally along pecten pubis

SUPERFICIAL INGUINAL RING
- A hiatus superolateral to pubic crest, triangular, with long axis parallel to deep aponeurotic fibres. Smaller in female
- Base is pubic crest, sides aponeurotic crura. Lateral crus is strong, attached to pubic tubercle, curved into a groove for sperm cord. Medial crus thin, flat, attached to the front of symphysis pubis, interlacing with is fellow

EXTERNAL OBLIQUE
- Free post border (not attached to thoracolumbar fascia)
- Free border is inguinal ligament

THORACOLUMBA FASCIA: trilaminar
- Anterior layer: attached to ant surfaces of lumbar TP, to iliolumbar lig, to apex & lower border of rib 12
- Middle layer: to tip of TP
- Post layer: to tip of SP, enveloping intrinsic mm

INTERNAL OBLIQUE
- Muscular attachment to thoracolumbar fascia, lat 2/3 of inguinal lig, ant 2/3 of iliac crest.
- (It is attached to iliac fascia (which is adherent to inguinal lig here), not directly to inguinal lig.)
- Lowermost fibres (from inguinal lig) arch over spermatic cord, become tendinous and attached with part of transversus to medial part of pecten and pubic crest (Conjoint tendon)

CREMASTER:
- loose muscle fasciculi lying along sperm cord, united by areolar tissue to form crematerіc fascia around cord and testis within ext sperm fascia.
- Continuous with medial edge of int obliq

TRANSVERSUS ABDOMINIS
- Attached to lat 1/3 of inguinal lig, ant 2/3 of iliac crest, thoracolumbar fascia, internal aspect of lower 6 costal cartilages
- Lower fibrers contribute to falx inguinalis, end in "conjoint tendon"

FALX INGUINALIS
Conjoint tendon, attached to pubic crest and pecten (the latter often missing), fuses with ant wall of rectus sheath

RECTUS ABDOMINIS
Costal cartilages 5-7 to pubic crest and tubercle
Three tendinous intersections (adherent to ant rectus sheath only)
Medial border of rectus adjoins linea alba, lat border Is linea semilunaris from tip of 9th costal cartilage to pubic tubercle

RECTUS SHEATH
- Formed by the aponeuroses of anterolateral muscles.
- Arcuate line (of Douglas) between umbilicus and pubis
- contains pyrimidalis, sup & inf epigastric Vx & terminal parts of lower intercostal nerves

PYRAMIDALIS
- Ant to rectus and in its sheath, attached by tendinous fibres to the front of pubic body and ant lig of symphysis.

- It lat border inclining medially, its pointed end embedded in linea alba midway between umbilicus and pubis. Anson found it absent in 17.7%

LINEA ALBA
Narrow below the umbilicus, broader in supraumbilical part (because recti diverge)

TRANSVERSALIS FASCIA
- Thin areolar stratum between transversus and extraperitoneal fat
- Fuses with ant lamina of thoracolumbar fascia, continuous with fascia iliaca.
- It descends with femoral Vx as the femoral sheath

DEEP INGUINAL RING
- in fasc transversalis
- midway between ASIS and symphysis, about 1/2 inch above inguinal lig.

INGUINAL CANAL
contains spermatic cord/round lig and ilioinguinal nerve
Oblique, about 4cm long, slants inferomedially, parallel to inguinal lig
Strength: two rings do not coincide. Post wall strengthened by falx inguinalis & reflected inguinal lig directly behind superf ring. Int obliq overlaps deep ring.
Fibres of int obliq & transversus arching over the canal are constantly active in standing, any increase in intra-abdominal pressure augments contraction of int oliq (and possibly transvesus)

WALLS OF INGUINAL CANAL

	Lat third	**Middlethird**	**Medial third**
Post wall	Transv fascia Deep ring	Transv fascia	Transv fascia conjoint tendon
Roof		Arching fibres of Int Obliq & Transv	
Ant wall	Int Obl muscle & Ext Obl apon	Ext Obl apon	ExtObl apon, superf ring
Floor	Inguinal lig	Inguinal lig	Inguinal lig

TRANSMITS IN FEMALE

Round lig
Three coverings
Funiculus vaginalis (obliterated processus vcaginalis)

TRANSMITS IN MALE

Vas
Testicular a
A to the vas
A to cremaster m
Pampiniform plexus
Lymphatics
Genital br of genitofemoral
Ilioinguinal n through ext ring only
Symp nerves to epididymis, vas and testis

LAB CLASS 4: HIP JOINT and ASSOCIATED MUSCLES

LEARNING ACTIVITIES

HIP JOINT

1. Observe a demonstration of the HIP BONE identifying the ilium, ischium and pubis, iliac crest, anterior superior iliac spine (ASIS), anterior inferior iliac spine (AIIS), iliac tubercle, posterior superior iliac spine (PSIS), posterior inferior iliac spine (PIIS), iliac tuberosity, auricular and gluteal surfaces, gluteal lines, iliac fossa, iliopubic eminence, acetabulum, body, pubic crest and tubercle, superior and inferior rami of the pubis, greater and lesser sciatic notches, ischial spine, ischial tuberosity and ramus of the ischium, pecten pubis, arcuate line, obturator foramen.

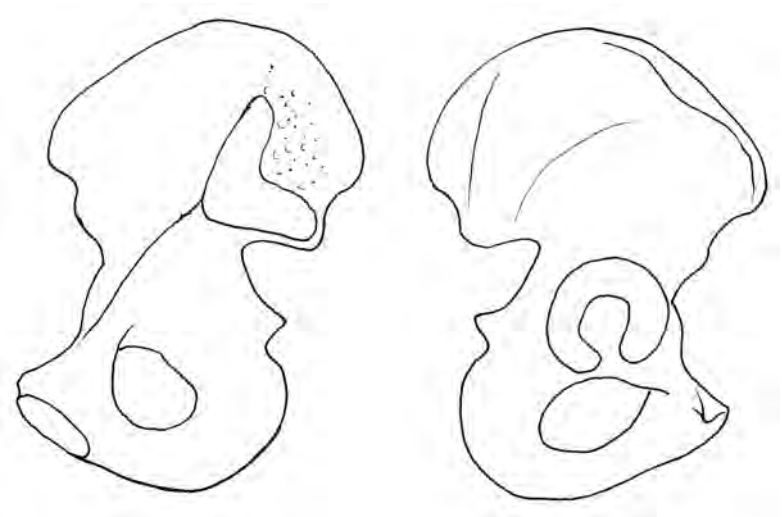

2. Palpate and identify on colleagues and/or self, the iliac crest, iliac tubercle, ischial tuberosity, ASIS and pubic tubercle. From these findings correctly orientate the hip bone (both AISIS's and pubic tubercles on a coronal plane) and determine the location of the pelvic inlet.
3. Observe a demonstration of the articulated pelvis, model and prosections, identifying the lumbosacral and sacroiliac joints, pubic symphysis, the iliolumbar ligament, interosseous sacroiliac, sacrotuberous and sacrospinous ligaments. Deduce the role of each ligament.
4. On the UPPER END OF THE FEMUR, identify the head with the fovea for the ligament of the head of the femur, neck, greater trochanter, trochanteric fossa (for attachment of obturator externus), lesser trochanter, intertrochanteric line, intertrochanteric crest, quadrate tubercle, pectineal line (continuing distally from the lesser trochanter) and linea aspera. Follow the lateral lip of the linea aspera (for attachment of vastus lateralis) as it passes by the gluteal tuberosity to end at the top of the greater trochanter, and the medial lip (for vastus medialis) as it becomes spiral line.

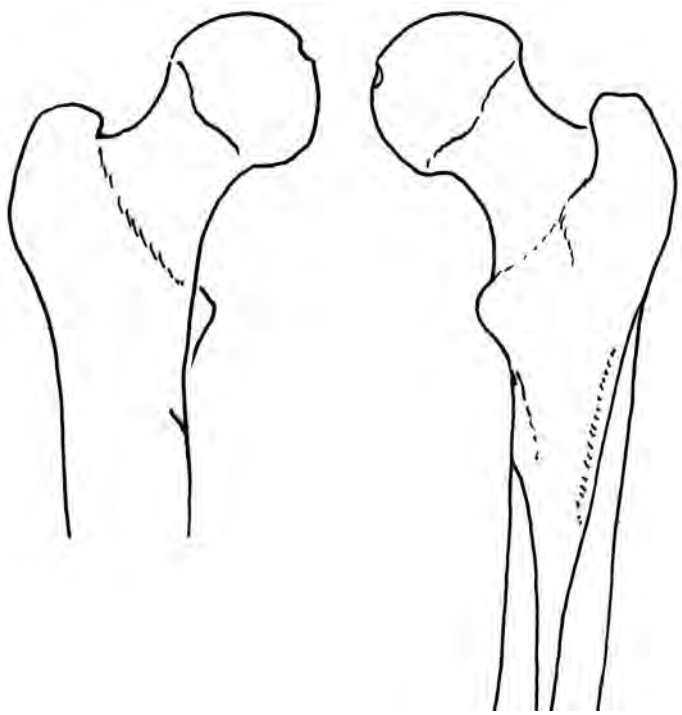

5. Observe a demonstration of the bony features, capsule and ligaments of the hip joint on bones, prosected specimens and models of the hip joint.

6. Examine prosected specimens and models of the hip joint. Identify the acetabular labrum, transverse acetabular ligament (bridging the acetabular notch and providing some attachment for the ligament of the head of femur), the iliofemoral (Y-shaped), pubofemoral and ischiofemoral ligaments, and the ligament of the head of the femur. Note that the inferior band of the iliofemoral ligament and ischiofemoral ligament twists around the neck of the femur. Explain why they are responsible for the stability of the hip joint.
7. Participate in group discussion on potential movements at the hip joint, on the basis of conformation of bony surfaces and the disposition of ligaments. What factors affect the stability of the hip joint? In what position is it most likely to dislocate and why? What movement is resisted by the (i) iliofemoral ligament and (ii) the pubofemoral ligament?
8. With colleagues study radiographs of the pelvis and hip joint and identify bony features listed in L.A.'s 1 and 4.

GLUTEAL MUSCLES

9. Observe the posterior aspect of the specimen. Identify the gluteus maximus, note in particular that only ¼ of the inferior muscle fibres are attached to the gluteal tuberosity on the femur, the rest is attached to fascia lata and iliotibial tract. When this muscle is retracted, the following muscles are visible almost on the same plane: gluteus maximus, medius and minimus, piriformis, obturator internus (tendon), superior and inferior gamelli and quadratus femoris. Revise with your colleague their bony attachments.
10. Note the superior gluteal vessels and nerve emerging above the piriformis, the inferior gluteal vessels and nerve, sciatic nerve, posterior femoral cutaneous nerve, pudendal vessels and nerve below the piriformis.
11. Observe the anterior aspect of the specimen. Identify the tensor fasciae latae attaching to the fascia lata and iliotibial tract and covering the gluteus minimus.
12. What are the pelvitrochanteric muscles? Why are they called lateral rotators of the hip joint? What is the main function of the gluteus medius and how would you demonstrate its paralysis (Trendelenberg's test)? What would result from simultaneous contraction of gluteus maximus and tensor fasciae latae?

13. Identify all the features of the hip bone, femur and the hip joint on X-rays

Materials: Articulated skeleton, hip bone, articulated pelvis, femur, tibia, prosected specimens, radiographs.

BONES OF THE LOWER LIMB

HIP BONE:

ILIUM Iliac crest: ASIS - AIIS - Tubercle
Anterior border: AIIS — Post. border: PIIS, contributes to Greater sciatic notch
Arcuate line — Iliac tuberosity, auricular surface (articulating with sacrum)

ISCHIUM Part of greater sciatic notch - Lesser sciatic notch - Ischial tuberosity — Ramus

PUBIS Body: symphysis, pubic crest and tubercle — Superior and inferior rami

OBTURATOR FORAMEN - obturator membrane

ACETABULUM Acetabular notch, acetabular fossa, lunate surface

SACRUM:

Five segments.Promontory, superior articular processes, laminae, ala, sacral foramina, cornua

Pelvic surface: anterior sacral foramina

Dorsal surface: Median sacral crests (spinous tubercles)
Intermediate sacral crest (articular tubercles)
Lateral sacral crest (transverse tubercles)
Posterior sacral foramina

Lateral surface: auricular surface (articulating with ilium)

Apex: articulates with coccyx - cornua

FEMUR:

HEAD Hemisphere, directed upwards, medially & slightly forwards
Anteverted, angle of femoral torsion (15 degrees)

GREATER TROCHANTER Trochanteric fossa (for Obt. Externus)
Attachment sites for pyriformis, gluteus minimus, gluteus medius

LESSER TROCHANTER attachment for psoas & iliacus

NECK Angle of inclination 125 degrees
Intertrochanteric LINE, spiral line (for vastus medialis)
Intertrochanteric CREST, quadrate tubercle
Posterior surface: lateral 1/3 extracapsular, groove for Obt Externus.

SHAFT long axis at 10 degrees to sagittal. Linea aspera - Gluteal tuberosity
Pectineal line - Posterior concavity (for muscles)

LOWER END Popliteal surface - Medial & lateral condyles - Intercondylar fossa

SACROILIAC JOINT

Synovial joint. — Articular surfaces: Hyaline cartilage on sacrum, Fibrocartilage on ilium

Ligaments: Ant, Post, Interosseous sacroiliac ligaments
Sacrotuberous & sacrospinous ligaments
(Iliolumbar ligaments)

HIP JOINT

Ball-and-socket joint

Acetabular labrum — Fibrous capsule - Zona orbicularis

LIGAMENTS: Transverse acetabular ligament
Iliofemoral ligament: inverted Y-shaped, from lower part of AIIS
Pubofemoral ligament: from iliopectineal eminence
Ischiofemoral ligament: from ischium
Ligt of the head of femur: to fovea

MOVEMENTS: Flexion - Extension — Abduction - Adduction
Medial & lateral rotations — Circumduction

NOTE: Stability depends also on atmospheric pressure
Anterior aspect: fewer muscles, strong ligaments
Posterior aspect: strong muscles, fewer ligaments
Position of instability: flexion and adduction (sitting crossed legged)

PUBIC SYMPHYSIS

Cartilaginous joint. — Interpubic disc of fibrocartilage — **Ligts**: Superior pubic & Arcuate pubic ligs.

The Hip Joint

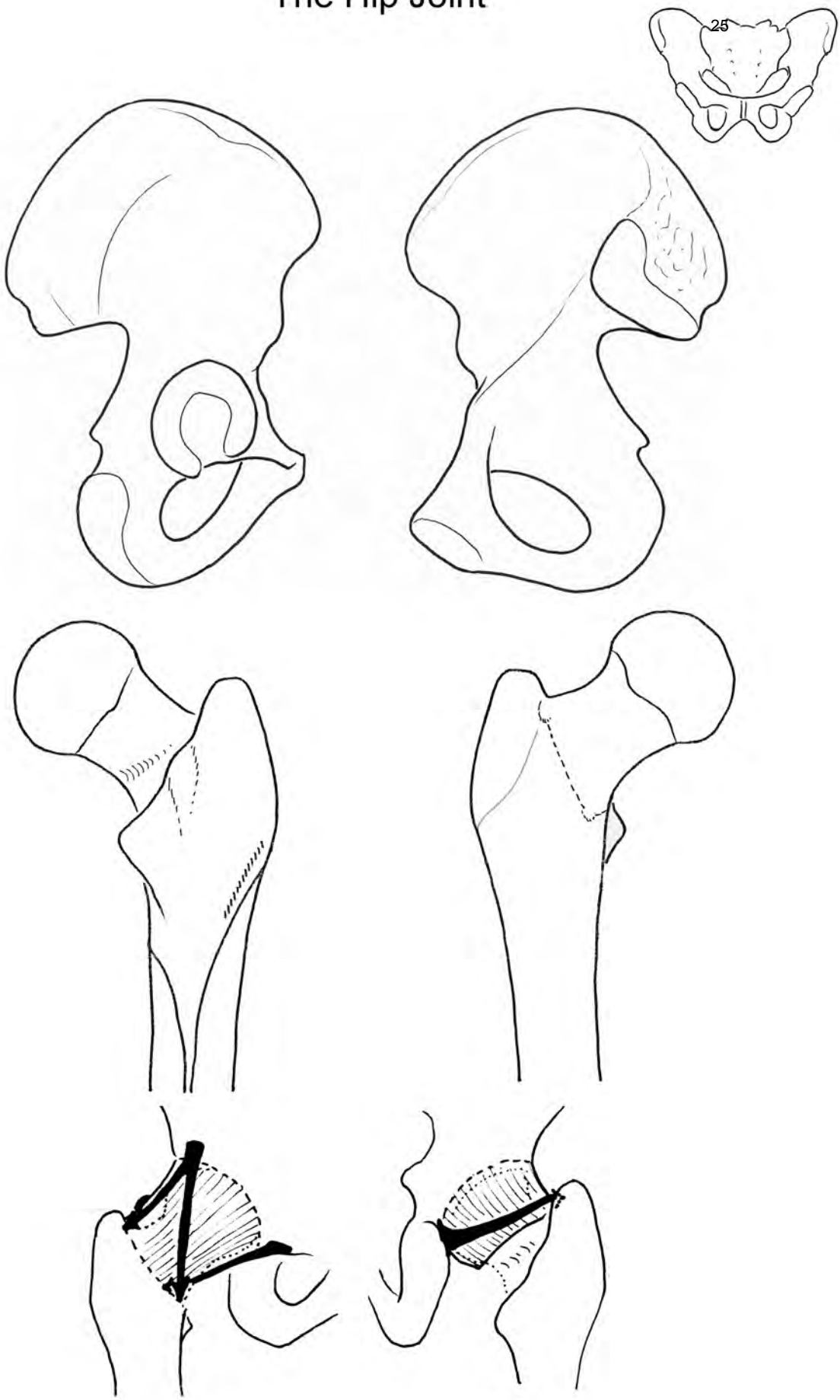

THE HIP JOINT

- Ball-and-socket joint
- Head of femur: > ½ sphere, anteverted (14 degrees)
- Acetabulum: directed obliquely forward (40 degrees to sagittal) and downward (60 degrees to horizontal)
- Neck of the femur: angle of inclination (125 degrees)

ACETABULUM:

- Lunate surface (*articular*) and acetabular fossa (*non-articular*)
- Acetabular notch
- Acetabular labrum deepens the bony acetabulum
- Transverse ligament of the acetabulum bridges the gap of acetabular notch

FIBROUS CAPSULE:

- Strong
- Attachment: margin of acetabular labrum and transverse acetabular ligament, intertrochanteric line, posterior aspect of femoral neck
- Composed of longitudinal fibres and circular fibres (zona orbicularis)

SYNOVIAL MEMBRANE

Ensheathes ligament of the head of the femur

LIGAMENTS:

1. **Transverse acetabular** ligament
2. **Iliofemoral lig** (Y-shaped lig): inverted Y, thick vertical bands and thin central part, attached to lower part of AIIS and intertrochanteric line
3. **Pubofemoral** ligament: from body of pubis and adjacent part of superior ramus, to lower surface of femoral neck
4. **Ischiofemoral** lig: from ischium (behind and below acetabulum) to greater trochanter, deep to iliofemoral ligament
5. **Ligament of the head of femur**: from each side of acetabular notch and floor of acetabular fossa to fovea on femoral head

NOTES THAT:

- Stability of the hip joint depends on: bony configuration, atmospheric pressure, and ligaments
- Anterior aspect: fewer muscles, strong ligaments. Posterior aspect: strong muscles, fewer ligaments
- Ligaments SPIRAL AROUND THE NECK: extension winds up these ligaments and holds the femur tightly into acetabulum (close-pack position). Position of instability: hip flexed and abducted
- Compression force across the hip joint produced by body weight AND the force of hip abductors. Rydell (1973) recorded force up to x5 times body weight in running. Normal neck fractures when femoral head is loaded > 12-15 times body weight!

LAB CLASS 5: FEMUR AND THIGH

LEARNING ACTIVITIES

THE HIP BONE and THE FEMUR

1. Identify the following features of the femur: lesser trochanter, pectineal line, linea aspera, spiral line, adductor tubercle, popliteal surface, the femoral condyle and intercondylar notch.
2. Review the following features of the hip bone: ASIS, AIIS, pubic tubercle, ischipubic ramus, ischiopubic ramus.

ANTERIOR COMPARTMENT OF THE THIGH (Femoral nerve)

3. Identify the following structures attaching to and near the ASIS: inguinal ligament, tensor fascia latae, sartorius. Follow the sartorius to its attachment on the tibia and note that it crosses anterior to the hip joint and posteromedial to the knee joint, hence it flexes the hip and knee joints and laterally rotates the thigh.
   Observe that at the front of the inguinal region, under the inguinal ligament are iliacus and psoas and pectineus.
4. The bulk of the front of the thigh is formed by the four heads of the quadriceps. Follow the rectus femoris from its attachment on AIIS, retract it to one side to see the other three heads, the vastus lateralis, vastus medialis and vastus intermedius between them. You cannot see the reflected head of the rectus femoris above the acetabulum. Trace the vastus lateralis to the posterior attachment on the linea aspera and note that it ascends up to the greater trochanter. Trace the attachment of the vastus medialis to its posterior attachment on the medial lip of linea aspera and spiral line. All four heads attach together as the patellar tendon onto the patella, note that the vastus medialis extend further down to the medial side of the patella. This part of the muscle has the fibres running more horizontally, it is called vastus medialis obiquus and helps prevent lateral dislocation of the patella. The rectus femoris crosses in front ogf the hip joint so it also flexes the hip joint in addition to working with the rest of the quadriceps to extend the knee.

THE MEDIAL COMPARTMENT OF THE THIGH (Obturator nerve)

5. Observe the anterior aspect of the specimens of the lower limb and thigh. Identify the pectineus, follow it to their attachment below the lesser trochanter and note its relation there with the ilio-psoas tendon. Where is the muscle attached to the hip bone and femur?
   On the medial aspect of the thigh, identify the gracilis. Note its proximal and distal attachments on the ischiopubic ramus and the tibia.
   Identify the adductors arranged in three layers: adductor longus, brevis and magnus. Review their bony attachments. Identify the two parts of adductor magnus, the *adductor part* (attached to the linea aspera) and the *hamstring part* (attached to the adductor tubercle of the femur, supplied by the sciatic nerve), and the adductor hiatus between the latter and the adductor.
6. Why is the ischiofemoral head of adductor magnus called “hamstring part”? Which muscle(s) would most likely be affected in a "*groin strain*" injury?

THE HAMSTRINGS (Sciatic nerve)

7. Identify on the hip bone the ischial tuberosity, ischiopubic ramus. Compare it with the diagram below to locate the muscle attachments on the bone.
8. Identify the three hamstrings. The semimembranosus and semitendinosus are on the medial side. Note their aponeurosis and tendons, their relations with each other, and in particular their attachments to the tibia.
   Note that the semimembranosus is attached to the edge of the tibial plateau and sends an expansion upwards across the knee joint, the oblique popliteal ligament. The semitendinosus is attached further down on the anteromedial aspect of the tibia. See how it is attached near the tendons of sartorius and gracilis to form the so-called *pes anserinus* (goose feet)
9. Identify the biceps on the lateral side with its long and short heads and its attachment on the fibula.
10. Discuss with your tutor the actions of bi-articular muscles like the hamstrings, how flexion of the hip joint limits extension of the knee joint and expose the ham strings to injury.

FEMORAL TRIANGLE

11. Identify the structures forming the boundaries of the femoral triangle:
    - Base: inguinal ligament from ASIS to PT.
    - Walls: medial borders of sartorius and adductor longus.
    - Floor: pectineus and iliopsoas
    - Roof: cribriform fascia, penetrated by great saphenous v.

12. Identify its contents: femoral nerve, artery, vein and canal (lateral to medial). Femoral sheath is continuous with the fascia transversalis, contains femoral artery & vein and canal but not the nerve.
13. Identify the femoral canal. Observe that in the space behind the inguinal ligament are found from lateral to medial: iliacus and psoas and the femoral nerve, pectineus. The medial part of this is occupied by the femoral sheath which has three compartments for the femoral artery, femoral vein and an empty compartment, femoral canal. Hernia through this empty compartment is called femoral hernia.

ADDUCTOR CANAL (SUSARTORIAL CANAL)

14. It begins from the apex of femoral triangle and ends at the adductor hiatus, bounded laterally by vastus medialis, posteriorly by adductors longus and magnus and roofed by sartorius and a strong aponeurosis connecting the vastus medialis and adductors.
15. Its contents: femoral artery and vein, two branches of femoral nerve (saphenous nerve and nerve to vastus medialis
16. Identify the labelled structures in the cross section below. Highlight the adductor canal. (Answers: From A to L are V. lateralis, rectus femoris, V. intermedius, V. medialis, sartorius, Adductor longus, A. magnus, gracilis, Short head of biceps femoris, long head of biceps, semitendinosus, semimembranosus. From 1 to 5: Anterior femoral cutaneous nerves, nerve to V. medialis, saphenous n, femoral artery, femoral vein, sciatic nerve, posterior femoral cutaneous nerve)

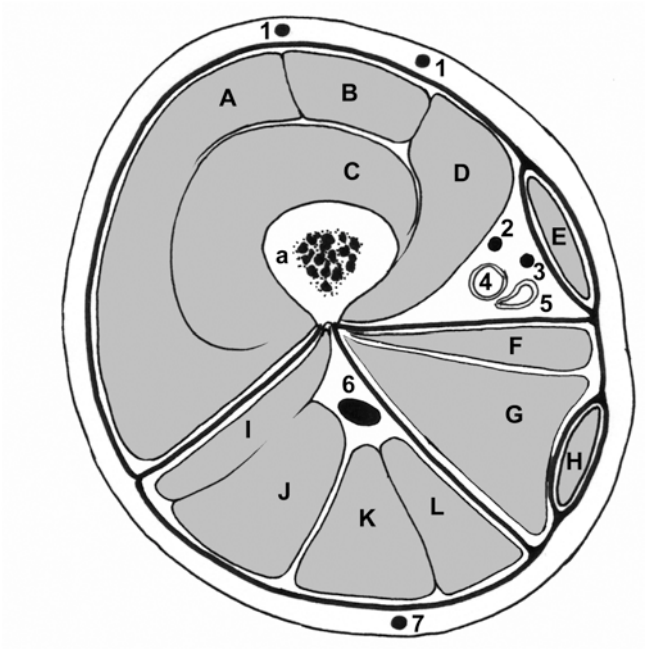

POPLITEAL FOSSA

17. Discuss with your tutor the boundaries of the popliteal fossa: the hamstrings above, two heads of the gastrocnemius muscle below. The floor is formed by the popliteal surface of the femur, capsule of the knee joint, and popliteus muscle
18. Identify the major contents of the popliteal fossa: tibial and common peroneal nerves, popliteal vein and artery and note their relative positions. The small saphenous vein empties into the popliteal vein in this fossa.

Materials: Femur, prosected specimens showing musculature of thigh.

MUSCLES OF HIP AND THIGH

ILIACUS	Iliac fossa	Lesser trochanter & below	Hip fexion
PSOAS MAJOR	Lumbar vertebrae	Lesser trochanter	Hip flexion

MEDIAL COMPARTMENT (ADDUCTORS)

1 PECTINEUS	Pecten pubis	lPectineal line	Add+ Flex thigh
2. ADD LONGUS	Pubis	Linea aspera	Adducts thigh
3. ADD BREVIS	Inf ramus of pubis	Linea aspera	Adducts thigh
4. ADD MAGNUS	• Ischiopubic ramus	Linea aspera	Adducts thigh
	• Ischial tuberosity	Adductor tubercle	Extends thigh
GRACILIS	Pubis	Tibia	Adductsthigh

ANTERIOR COMPARTMENT

V. INTERMEDIUS	Femur	Patella, lig patellae to tibial tuberosity	Ext. leg
V. LATERALIS	Linea aspera	As above	Ext. leg
V. MEDIALIS	Spiral line, l. aspera	As above	Ext. leg stabil.patella
RECTUS FEMORIS	AIIS	As above	Ext. leg, flex. thigh
SARTORIUS	ASIS	Tibia	Flexes thigh & leg, rotates thigh laterally
TENSOR F. LATAE	between ASIS & AIIS	Iliotibial tract	Flexes & stabil. thigh

GLUTEAL MUSCLES

GLUTEUS MAXIMUS	post to post gluteal lline, sacrum, sacrotuberous lig.	Iliotibial tract and glut. tuber.	Extends & stabilizes thigh (lat rot.)
GLUTEUS MEDIUS	between ant & post gluteal lines	Gr troch. (lat border)	Abduction and med. rotation
GLUTEUS MINIMUS	ant. to ant gluteal line	Gr. troch. (ant border)	As above

PELVITROCHANTERIC MUSCLES (LATERAL ROTATORS)

PIRIFORMIS	sacrum (pelvic surface)	Gr troch. (sup border)	Abd. + Lat rotation.
OBT INTERNUS	pelvic surf of obt. for. & membr.	Gr. troch.	Lat. rot
GEMELLI, SUP & INF	ischium (spine & tuberosity)	As above	Lat. rot.
OBT EXTERNUS	Ext. surf of obt. for. & membr.	Troch. fossa	Lat. rot
QUAD. FEMORIS	Ischium	Quadrate tubercle	Lat. rot

HAMSTRING MUSCLES

SEMIMEMBRANOSUS	Ischial tuberosity	Tibia	Hip ext, knee flex, med rot of leg (knee semiflexed)
SEMITENDINOSUS	Ischial tuberosity	Tibia	As above
BICEPS			
@ Long head	Ischial tuberosity	Fibula (Head)	Hip ext, knee flex lat .rot of leg when knee semiflexed
@ Short head	L. aspera	As above	As above

LAB CLASS 6: KNEE JOINT AND ASSOCIATED ANATOMY

LEARNING ACTIVITIES

LOWER END OF THE FEMUR

1. Identify and label on the drawing the following features: supracondylar lines, lateral and medial condyles, epicondyle, patellar surface (extending higher into the shaft than on the lateral side) and tibial surface of the femoral condyles, intercondylar fossa, medial epicondyle, lateral epicondyle just above the groove for popliteus tendon.
2. Look at the lower end of the femur from below and note that the lateral condyle is shorter anteroposteriorly than the medial condyle.

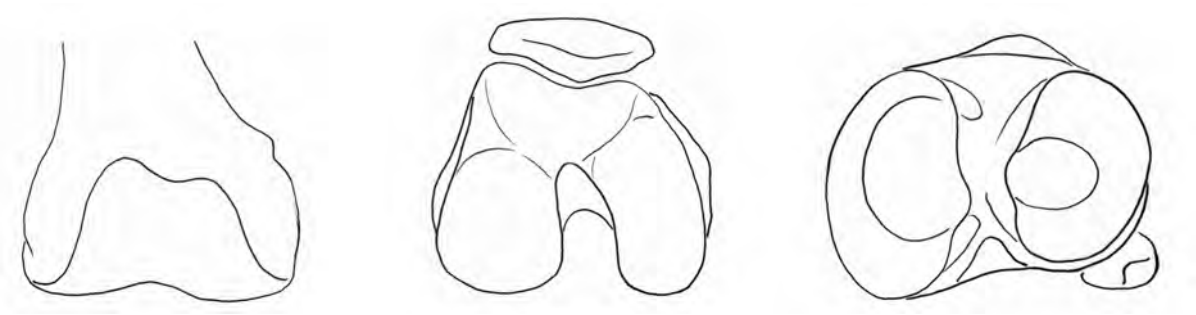

UPPER END OF THE TIBIA

3. Identify the tibial “plateau” with the medial (longer anteroposteriorly) and lateral condyles (shorter anteroposteriorly), tibial tuberosity, articular facet for the fibula (facing lateroinferiorly), soleal line limiting the popliteal surface (for popliteus muscle).
4. Look at the superiuor surface of the tibia, note the articular surfaces of the condyles, anterior and posterior intercondylar areas, medial and lateral intercondylar eminences with tubercles (easily seen on AP X-rays)

UPPER END OF THE FIBULA

5. Put the fibula together with the corresponding tibia and appreciate that the fibula is posterolateral and does not articulate with the femur at all. Identify the facet for articulation with the tibia (facing mediosuperiorly and anteriorly), this is a synovial joint.
6. Identify the apex of the head of the fibula (styloid process)

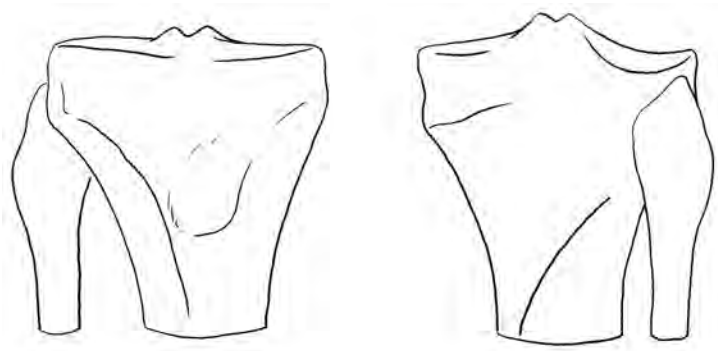

PATELLA

7. Identify the anterior surface with impressions of the fibres of the quadriceps tendon/ligament, posterior surface with a broader and deeper lateral articular surface and a narrower medial surface, apex
8. Identify as many bony features as possible on radiographs of the knee joint

KNEE JOINT

9. With colleagues examine models, prosected and plastinated specimens of the knee joint. Note the extent and attachments of the knee joint capsule, note that it is deficient anteriorly where the patella and quadriceps mechanism are, and it has a hole for the passage of the popliteus tendon.
10. Identify the lateral and medial menisci and their attachments to the tibia by their anterior and posterior horns. Identify the transverse ligament connecting the menisci anteriorly. What is the coronary ligament?
11. Identify the collateral ligaments of the knee and their attachments. Note that the medial collateral ligament overlies directly and is attached to the medial meniscus but the lateral collateral ligament is separated from the lateral meniscus by the tendon of popliteus
12. Identify the oblique popliteal ligament and arcuate popliteal ligament (not present on most of our

specimens) which reinforce the posterior capsule.

13. Identify the anterior cruciate ligament (ACL) and posterior cruciate ligament (PCL). Review their attachments to the tibia and femur, note that they are named after their tibial attachment (eg. anterior cruciate ligament is attached to the anterior intercondylar area) and that they cross (hence the name “cruciate”) when viewed from the side, but they lie in two planes when viewed from above.
14. Identify the posterior meniscofemoral ligament which lies on the posterior aspect of the PCL. The anterior meniscofemoral ligament is not visible on our prosections or models.
15. Discuss the abnormal movement of the tibia in case of rupture of ACL and PCL (drawer sign) and rupture of medial collateral ligament (varus instability)

BURSAE

16. Of all the bursae around the knee joint, identify the location of the suprapatellar, prepatellar, superficial and deep infrapatellar bursae. Be aware of the bursae between overlapping muscles and tendons and between tendons and bone such as those around the pes anserinus and

MUSCLES OF THE KNEE JOINT

17. Review the function of vastus medialis obliquus in stabilising the patella
18. Identify the iliotibial tract which is attached to a small tubercle lateral to the tibial tuberosity. Identify it as a round long raised strip on the lateral side of your patella. Move the knee joint specimen to see it sliding anteroposterior over the lateral femoral condyle during flexion-extension of the knee. What is the Iliotibial band syndrome (or iliotibial band friction) syndrome?
19. Popliteus: identify the muscle and discuss its attachment and action in “unlocking” the knee joint at the beginning of knee flexion
20. Based on what has been covered in the lecture, discuss with your tutor the complex movement of the femur and tibia during flexion-extension of the knee joint, and the role of popliteus in “unlocking” the knee joint at the beginning of knee flexion

MUSCLES OF THE LATERAL COMPARTMENT OF THE LEG

21. Identify the lateral surface of the tibia which, after giving attachment to the peroneus longs (fibularis longus) and peroneus brevis (fibularis brevis), rotates in the lower quarter of the bone to become posterior. In the lower end of the fibula, identify the triangular articular surface for the talus facing medially, and the groove for the peroneal tendons peronei posterior to it.
22. Identify the peroneus longus and brevis, follow the tendons distally to see them strapped down by the superior and inferior peroneal retinacula. The peroneus brevis tendon is attached to the posterior end of the 5th metatarsal, the peroneus longus tendon hooks around the cuboid and traverse the sole of the foot to attach to the first metatarsal.

MUSCLES OF THE ANTERIOR COMPARTMENT OF THE LEG

23. Study the cross section of the leg below to appreciate that the so-called anterior compartment is in actual fact anterolateral in position.
24. Study the deep dissection of the leg to identify the proximal tibiofibular joint (synovial joint), interosseous membrane and the distal tibiofibular joint (fibrous joint).
25. Identify the tibialis anterior, extensor digitorum longus, and extensor hallucis which begins deep to the other two and peroneus tertius. Review their proximal and distal attachments. Follow their tendons to see them passing under the superior and inferior extensor retinaculum.
26. What is “shin splint”?

MUSCLES OF THE POSTERIOR COMPARTMENT OF THE LEG

27. Identify the superficial muscles which form the triceps surae: lateral gastrocnemius, medial gastrocnemius and soleus. Follow them to their common tendon: tendo calcaneus (Achilles tendon). Review their attachments. What is retrocalcaneal bursitis?
    Identify the plantaris, follow its long tendon to its attachment on the medial side of the tendo calcaneus.
    Note that the gastrocnemius crosses the knee joint and flexes the knee joint while the soleus does not.
28. Identify the three deep muscles: tibialis posterior which is attached to tibia and fibula and interosseous membrane, covered by the flexor hallucis longus (attached to the fibula) and the flexor digitorum longus (attached to the tibia). The tendon of tibialis posterior emerge under the flexor digitorum longus above the ankle.
    Follow the tendons till they pass through the “tarsal tunnel” under the flexor retinaculum which bound the following structures in order from above downward: tibialis posterior tendon, flexor digitorum longus tendon, posterior tibial artery, tibial nerve, flexor hallucis tendon

29. Xrays: identify all the above features of the knee joint on X-rays

SUMMARY & CROSS SECTION

There are **three compartments** of the leg, divided by inward extension of the deep fascia:

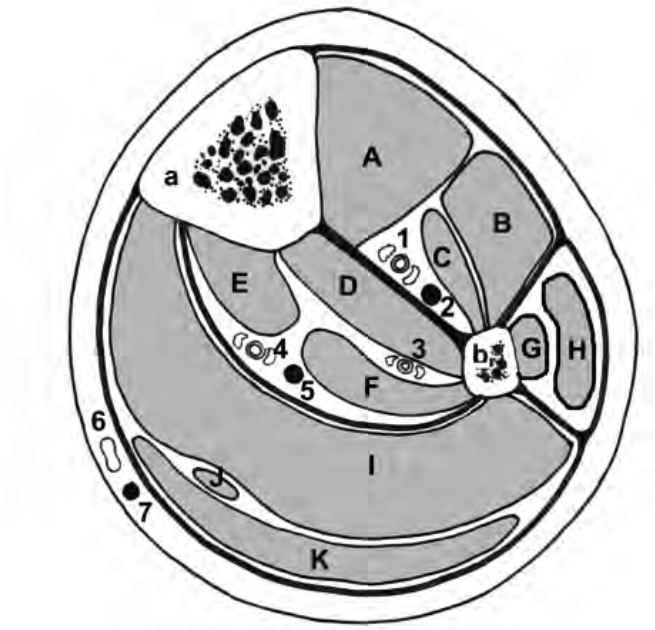

Compartment	Group	Action	Nerve
Anterior	Extensors	Dorsiflexion	Deep Peroneal
Lateral	Peronei	Eversion	Sup. Peroneal
Posterior	Flexors	Plantarflexion	Tibial

The **retinacula**:

- Superior extensor retinaculum (Tib Ant has its own compartment
- Inferior extensor retinaculum: Y-shaped
- Flexor retinaculum: boundary of tarsal tunnel
- Superior peroneal retinaculum
- Inferior peroneal retinaculum: continues inferior extensor retinaculum

Identify the labelled structures in the cross section of the leg below
(Answers: from A to K: tibialis anterior, extensor digitorum longus, extensor hallucis longus, tibialis posterior, flexor digitorum longus, flexor hallucis longus, peroneus brevis, peroneus longus, soleus, plantaris, gastrocnemius. From 1 to 7: anterior tibial vessels, deep peroneal nerve, peroneal vessels, posterior tibial vessels, tibial nerve, small saphenous vein, saphenous nerve)

Materials: Bones, models, prosected specimens, X rays of knee joint.

THE KNEE JOINT

1. **Femoropatellar** joint : plane joint - gliding
2. **Femorotibial** joint : synovial joint (hinge + some rotation)

ARTICULAR SURFACES

FEMUR: medial condyle - Lateral condyle (groove for popliteus tendon) - Intercondylar notch
Patellar articular surface (lateral side higher) - Tibial surfaces
PATELLA: lateral facet broader
TIBIA: Medial condyle - Lateral condyle (smaller, rounder) - Intercondylar area & eminences - Fibular facet.
Position of close packing: full extension

CAPSULE

Anteriorly: blends with expansions from vasti, absent at the front of the joint
Posteriorly: blends with origins of heads of gastrocnemius, gap for popliteus (which is intracapsular at its origin), strengthened by oblique popliteal ligament.
Attached to periphery of menisci (Coronary ligament)

SYNOVIAL MEMBRANE: Suprapatellar bursa - Cruciate ligaments are extrasynovial

LIGAMENTS

Ligamentum patellae
Oblique popliteal ligament (expansion from semimembranosus)
Arcuate popliteal ligament
COLLATERAL LIGAMENTS
- **Tibial** collat lig: firmly attached to edge of medial meniscus
- **Fibular** coll lig: not attached to meniscus
Relations to biceps & popliteus tendons
Both taut on extension
CRUCIATE LIGAMENTS, ant & post: named after their TIBIAL attachments

MENISCI

Medial (C-shaped) and **lateral** (almost circular)
Meniscofemoral ligament - Transverse ligament
Distorted & move during flexion-extension, follow femoral condyles in rotation

BURSAE

Suprapatellar, prepatellar, superficial & deep infrapatellar
Between capsule & heads of gastrocnemius, popliteal, semimembranosus

MOVEMENTS

Flexion, extension, medial & lateral rotations
Conjunct rotation (integral with flexion-extension) - Role of popliteus in "unlocking" the joint at the start of flexion
Muscles producing movements at the knee joint (Refer to your text)

Clinical aspects

- Instability due to ligamentous damage (lateral/medial stress test, drawer sign)
- Injury to the meniscus (medial meniscus more commonly damaged)

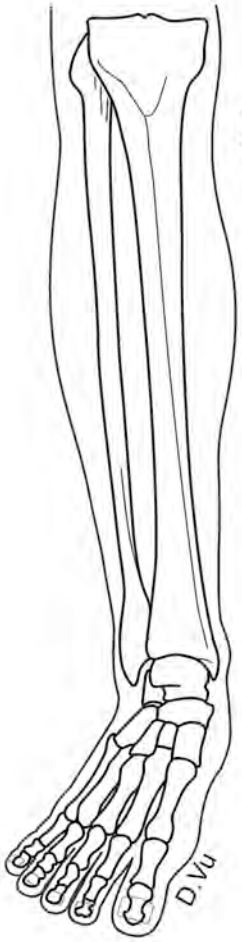
Extensor digitorum longus
D.Vu

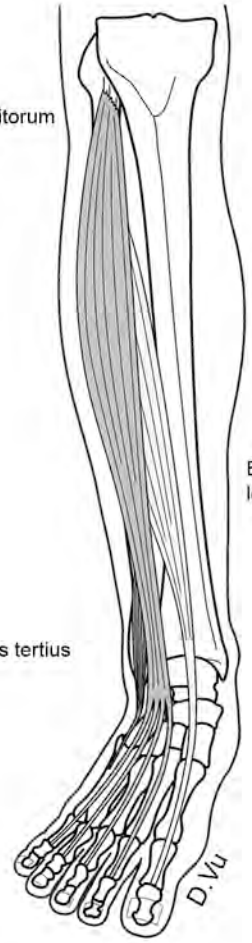
Ext. Hallucis longus
Peroneus tertius
D.Vu


Tibialis anterior
D.Vu

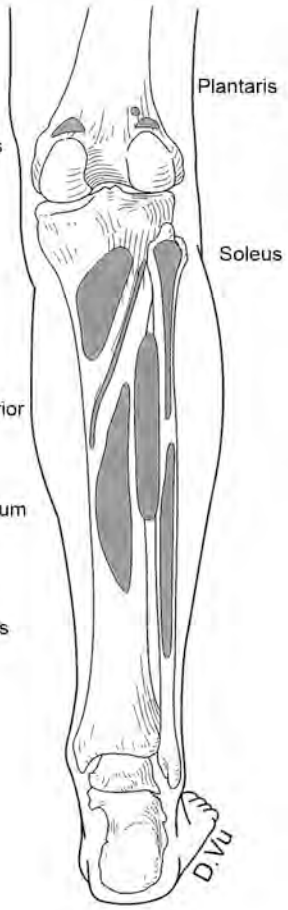
Plantaris
Gastrocnemius
Soleus
Popliteus
Soleus
Tibialis posterior
Flexor digitorum longus
Flexor hallucis longus
D.Vu

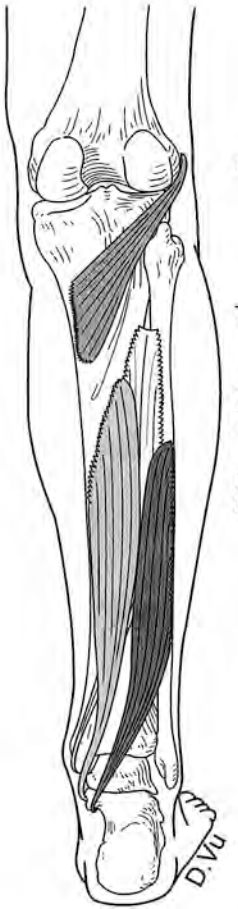
Popliteus
Tibialis posterior
Flexor digitorum longus
Flexor hallucis longus
D.Vu


FDL
TP
FHL

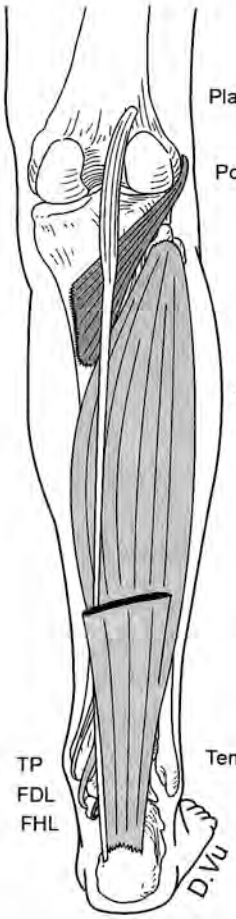
Plantaris
Popliteus
Soleus
Tendo calcaneus
TP
FDL
FHL
D.Vu

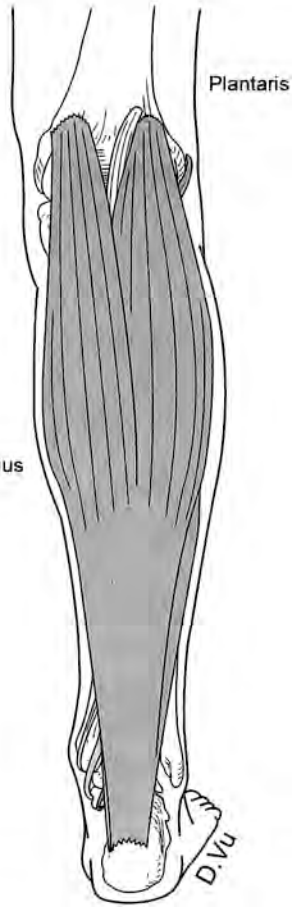
Plantaris
Gastrocnemius
D.Vu

LAB CLASS 7: ANKLE AND FOOT 1

LEARNING ACTIVITIES

BONES OF THE FOOT

1. With colleagues, examine an articulated foot and identify the tarsal bones and their features described below: talus and calcaneus (hindfoot), navicular, 3 cuneiforms, cuboid (midfoot). Similar to the hand, distal to the tarsus are the metatarsals and phalanges (forefoot). The joint between the hindfoot and midfoot is called midtarsal joint/transverse tarsal joint/Chopart's joint, the joint between the midfoot and forefoot tarsalmetatarsal joint/Lisfranc's joint
2. TALUS: the body/dome which has a middle groove and is wider anteriorly, and posterior calcanean articular facet for the calcaneus. The head, connected with the body by the neck, articulates with the calcaneus anteriorly, with the anterior and middle facets of the calcaneus inferiorly. Identify the *tarsal canal* which is formed by the *sulcus tali* and *sulcus calcanei* . It contains the interosseous ligament and widens laterally into *sinus tarsi*. Posteriorly it has a posterior process with a deep groove for the tendon of flexor hallucis longus (FHL)
3. CALCANEUS: Articulates with the cuboid anteriorly and has a prominent calcaneal tuberosity posteriorly. The superior surface has the posterior surface for the body of talus, separated by sulcus calcanei from the anterior and middle surfaces for the head and neck of talus.
   The inferior surface has a round anterior tubercle and two lateral and medial tubercles at the posterior end, the last two are weightbearing areas of the heel.
   Sustentaculum tali is a shelf of bone supporting the talus, it is grooved on its underside by the tendon of FHL. The tendon of flexor digitorum longus runs along the medial side of the sustentaculum. Put the talus on the calcaneus to see the continuity of the groove for FHL from the talus to the sustentaculum.
4. NAVICULAR articulates with three cuneiform anteriorly, has a prominent tubercle for attachment of tibialis posterior.
5. CUNEIFORMS: wider on the dorsal side thus responsible for the transverse tarsal arch, numbered from the medial one (which articulates with the 1st metatarsal)
6. CUBOID: has a deep groove for tendon of peroneus longus, articulates with the 4th and 5th metatarsals
7. METATARSALS. Underneath the head of the 1st metatarsal are two sesamoid bones. The 2nd is the least mobile because it is attached to the shorter middle cuneiform and jammed on the sides by the other cuneiforms. The 5th has a tuberosity at its base for the tendon of peroneus brevis.
8. PHALANGES

ARCHES OF THE FOOT

9. Identify the arches of the foot. The medial longitudinal arch is the higher of the two, and consists of the calcaneus, talus, navicular, cuneiforms and medial three metatarsals. The lateral longitudinal arch consists of the calcaneus, cuboid, and lateral two metatarsals. Remember that the skeleton of the foot may be relatively flexible if the plantar aponeurosis is slack, but can be converted into a more rigid, weight-bearing arch by tension on the aponeurosis, brought about by dorsiflexion of the toes.
   The transverse tarsal arch is a half dome in the mid part at the level of the cuneiforms.

DISTAL TIBIOFIBULAR JOINT

10. Is a fibrous joint (syndesmosis) with a strong interosseus ligament. Identify on the model and specimen the anterior and posterior tibiofibular ligaments, inferior transverse ligament

ANKLE JOINT/ TALOCRURAL JOINT

11. A hinge joint between the tibial and fibular malleoli and the body of talus. Observe the large triangular articular surface on the talus for the fibular malleolus and the comma-shaped surface for the tibial malleolus. Therefore the lateral malleolus extend further distally than the medial, this can be confirmed on your own feet.
12. Lateral collateral ligament: identify the anterior and posterior talofibular ligaments, the calcaneofibular ligaments
13. Medial collateral ligament: identify the deltoid ligament. You can only see the superficial layer which is attached to the neck of talus, sustentaculum tali, spring ligament, navicular and the back of talus. The deep layer has been described differently by different authors but in composed of fibres running from the tibia to the talus.

14. The joint is most stable in dorsiflexion because the wider part of the talar dome is forced in between the malleoli. The range of movement is variable, but it is ca 20-30° in dorsiflexion and 30-50° in plantar flexion.

SUBTALAR/TALOCALCANEAN JOINT

Between the posterior surfaces of the talus and calcaneus which are like sections of a cylinder (or truncated cone). The main ligaments that you can identify are interosseous ligament in the tarsal

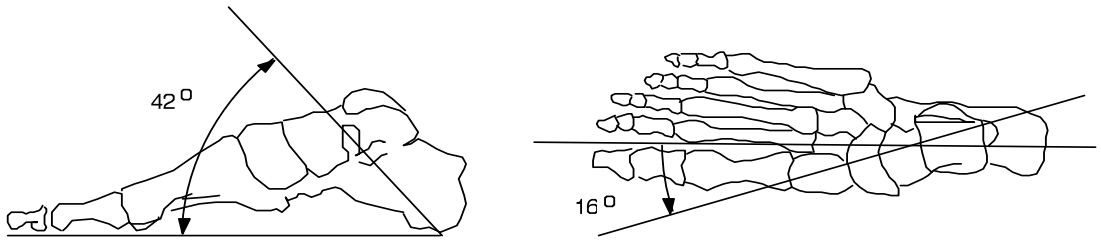

The axis of the subtalar joint makes an angle of about 42 degrees with the horizontal and 16 degrees with the sagittal plane.(Manter, 1941).

canal, and the cervical ligament in the sinus tarsi.

TALOCALCANEONAVICULAR (TCN) JOINT (Sometimes called subtalar joint!)

15. Ball and socket joint. Identify the articular surfaces of the TCN joint: head of talus, navicular bone, anterior and middle facets of the talus and corresponding facets of the calcaneus, and the spring ligament (Plantar calcaneonavicular ligament).
    Of all the ligaments, you only need to identify the bifurcate ligament on the model (from calcaneus to navicular and cuboid)

CALCANEOCUBOID JOINT

16. Articular surfaces are concavoconvex, so the joint is stable.
    Identify some important ligaments: bifurcate ligament, short plantar ligament (deeper) and long plantar ligaments (more superficial)

TRANSVERSE TARSAL/MIDTARSAL JOINT

17. This is the name given to the combined TCN and calcaneocuboid joints.
    Movements at this joint are inversion and eversion
    (Note that pronation is tilting of the angle of the heel and tibia opens outward, collapsing the medial longitudinal arch, and supination is the opposite movement)

18. Movements at the tarsal joints: at the first two tarsal joints (subtalar and TCN), the movements of inversion and eversion take place (ideally about the long axis of the foot), and also abduction and adduction (ideally about the axis of the tibia). But the real axis of rotation of the subtalar joint, (and the TCN joint) does not lie on either of these axes; in fact it is angled with respect to these axes, so that inversion and adduction occur together (and are produced by tibialis anterior and posterior). In the same way, eversion and abduction are linked (and produced by peroneus longus and brevis). Note that when the foot is on the ground, one refers to supination (lateral border down) rather than inversion, and pronation (medial border down) rather than eversion.

    Close-packing of tarsal joints: in supination (McConnail & Basmajian p.78)

19. Xrays: identify all tarsal bones and their features on X-rays

Materials: Bones of foot, X-rays, prosected specimens of subtalar joint and specimens showing ligaments and intrinsic muscles of foot.

TIBIOFIBULAR JOINT

SUPERIOR T-F JOINT

Plane synovial joint. Very small movements: the fibula slides and rotates

INFERIOR T-F JOINT

Fibrous joint.

Ligaments: T-F interosseous ligament
Reinforced by anterior and posterior T-F ligts

ANKLE JOINT = TALOCRURAL JOINT

Articular surfaces

On the tibial and fibular malleoli forming mortise clamping the tala body

TALUS: trochlear surface on body
Transverse width wider anteriorly thus close packed position is dorsiflexion
medial surface (for tibia, comma shaped)
lateral surface (for fibula, large, triangular)

Ligaments

Almost like a hinge joint: thus collateral ligaments

MEDIAL COLLATERAL LIGAMENT (MCL) = DELTOID LIGAMENT

Superficial and deep layers

From tibial malleolus to talus (anterior and posterior tibiotalar ligts), navicular, sustentaculum tali, spring ligament

LATERAL COLLATERAL LIGAMENT (LCL)

Three separate bands: anterior & posterior talofibular ligts, calcaneofibular ligt

Function

Movements are mostly dorsiflexion and plantar flexion with slight rotation possible

Note that axis is NOT transverse but rotated laterally and inclined laterally (lateral end lower because fibular malleolus extends further distally). So dorsiflexion bring the forefoot up & slightly laterally

LCL weaker than MCL. The anterior talofibular is the weakest

JOINTS AT THE ANKLE

TALOCRURAL JOINT

Hinge type.
Medial collateral lig (Deltoid lig)
Lateral collateral lig.
Movements: plantar and dorsiflexion

SUBTALAR (TALOCALCANEAN) JOINT

Talocalcanean ligs - Interosseous lig

TALO-CALCANEO-NAVICULAR JOINT

Ball: head of talus -Socket: navicular, ant articular surface of calcaneus, "spring" lig
Plantar calcaneonavicular lig ("spring" lig)
Bifurcated lig (calcaneocuboid + calcaneonavicular ligs)
Movements: gliding & rotation

CALCANEOCUBOID JOINT

Saddle-shaped - Movements: gliding, with conjunct rotation
Ligaments: Bifurcated lig
Short plantar lig - Long plantar lig (Note tunnel for peroneus longus)

TRANSVERSE TARSAL JOINT

Talonavicular joint + calcaneocuboid joint. Separate, only on the same line!

LIGAMENTS

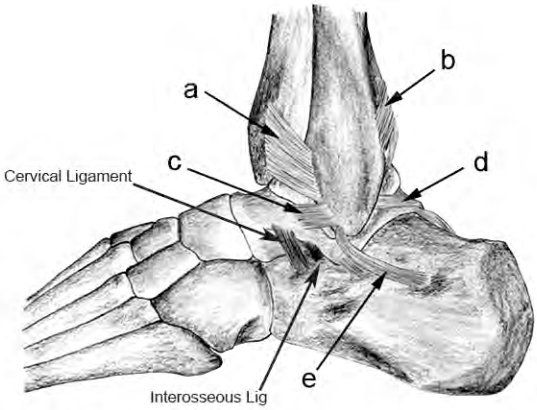

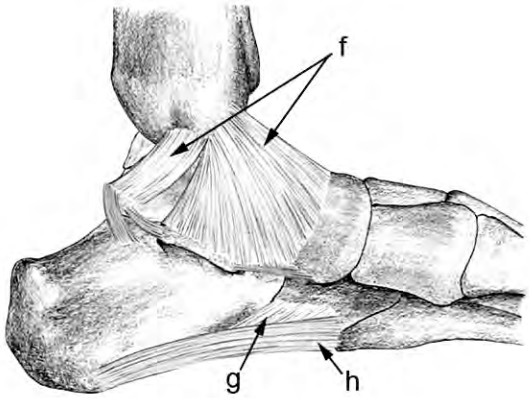

LATERAL VIEW:

a. Anterior tibiofibular ligament
b. Posterior tibiofibular ligament
c. Anterior talofibular ligament
d. Posterior talofibular ligament
e. Calcaneofibular ligament
(c+d+e = lateral collateral ligament)

MEDIAL VIEW:

f. Medial collateral/Deltoid ligament
g. Short plantar ligament
h. Long plantar ligament

Lateral View of the ankle

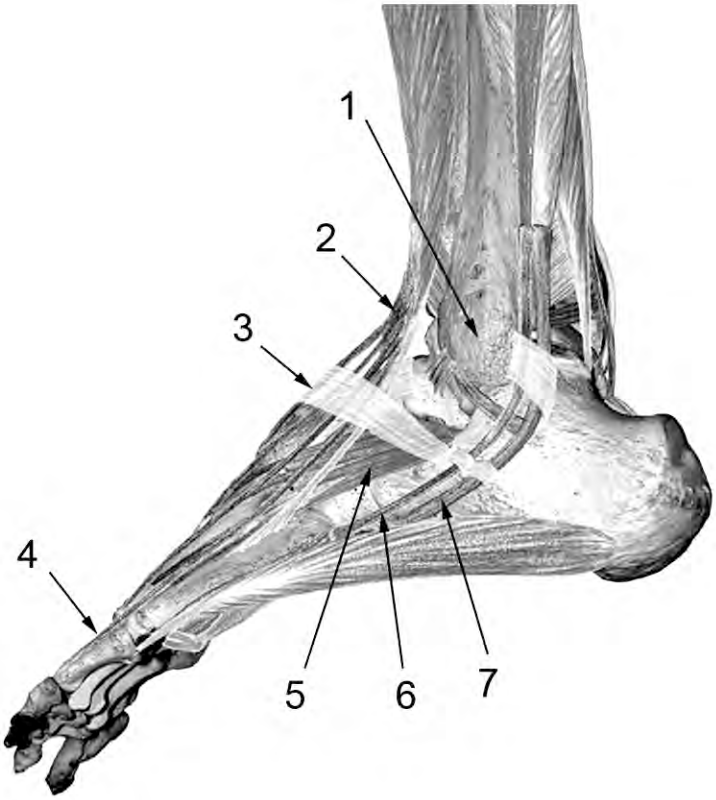

1. Lateral malleolus
2. Extensor digitorum longus
3. Extensor retinaculum
4. Extensor hallucis longus
5. Extensor digitorum brevis
6. Peroneus brevis
7. Peroneus longus

Dr. D. Vu 2006

LAB CLASS 8: FOOT 2 – LUMBOSACRAL PLEXUS

LEARNING ACTIVITIES

FASCIA OF THE FOOT:

1. ***Plantar aponeurosis***: homologous to palmar aponeurosis but it has no muscle acting on it. It runs forward from the calcaneus to attach on the plantar ligaments of the metatarso-phalangeal joints
   Dorsal fascia is thin

INTRINSIC MUSCLES OF THE FOOT

2. ***Dorsal muscle*** of the foot: I dentify the only one is *extensor digitorum brevis* on specimens and palpate it on your own feet. A separate belly for the hallux may be distinguished, sometimes referred to as *extensor hallucis brevis*.

3. ***The plantar muscles*** of the foot are divided into four layers. Identify the layers and understand the general topography of intrinsic muscles of the foot, NO knowledge of detailed attachments is required.

4. LAYER 1- Mnemonic: **AFA**
   Flexor digitorum brevis (comparable to FDSuperficialis in the hand, its tendons split around flexor digitorum longus tendons)
   Abductor hallucis and abductordigiti minimi

5. NEUROVASCULAR PLANE between layers 1 & 2, containing medial & lateral plantar vessels and nerves

6. LAYER 2 - Two tendons and associated muscles
   Flexor hallucis longus crossing deep to flexor digitorum longus (FDL)
   Attached to FDL are the flexor accessorius (quadratus plantae) posteriorly and the 4 lumbricals anteriorly

7. LAYER 3 - Mnemonic: **FAF**
   Flexor hallucis brevis and flexor digiti minimi brevis
   Adductor hallucis

8. LAYER 4 – 2 tendons and interossei
   Tendons of peroneus longus and tibialis posterior
   Dorsal interossei (DAB) and plantar interossei (PAD). Their arrangement follows the same principles as in the hand, except that the axis of the foot is through the 2nd metatarsal.

SUMMARY OF MUSCLES ACTIONS

Muscles acting on the ankle joint

DORSIFLEXION	PLANTAR FLEXION
	Gastrocnemius, Soleus, Plantaris
Extensor hallucis longus	Flexor hallucis longus
Extensor digitorum longus	
Peroneus tertius	Peronei
Tibialis anterior	Tibialis posterior

Muscles acting on the subtalar and midtarsal joint

INVERSION & ADDUCTION	EVERSION & ABDUCTION
Tibialis ant & post	Peronei longus, brevis and tertius
Flexor hallucis longus	Extensor digitorum longus (lateral part)
Flexor digitorum longus	

9. SOME COMMON DISORDERS OF THE FOOT
   - Flat foot (pes planus), pes cavus (very high longitudinal arch)
   - Simple Clubfeet (Talipes): talipes equinus (marked plantar flexion like a horse – T. calcaneus: marked dorsiflexion)
   - Combined talipes: T. equinovarus (heel also bent inward) – T. equinovalgus (heel also bent outward – T. calcaneovarus – T. calcaneovalgus
   - Hallux valgus: long axis of big toe turn laterally, usually resulting in bunion

LUMBOSACRAL PLEXUS

10. Note that the **lumbar plexus** is deep to the psoas major and formed by the ventral rami of spinal nerves L1-4
    Identify the following nerves on the posterior abdominal wall of deep abdomen specimens, referring to lecture handout for details.
    - *Iliohypogastric* n and *ilioinguinal* (L1): they are homologous to intercostal nerve and its collateral branch
    - *Genitofemoral* (L1,2): pierces psoas major
    - *Lateral femoral cutaneous* nerve (L2,3): runs deep to the inguinal ligament near the ASIS and emerges superficial to sartorius into the thigh
    - *Femoral* nerve (L2,3,4) emerges from the lateral border of psoas
    - *Obturator* nerve (L2,3,4) emerges from the medial border of psoas, passes through obturator canal with obturator vessels to enter the thigh
    - *Lumbosacral trunk* (L4,5): join the sacral plexus
    - Direct branches to psoas, quadratus lumborum (not seen on our specimens)

11. **Sacral plexus**: is in front of piriformis and continues directly into the sciatic nerve. The following branches can be identified on most of our specimens:
    - Sciatic nerve (L4-S3) made up of tibial nerve and common peroneal nerve. The latter innervate the short head of biceps and may run through or above piriformis
    - Posterior femoral cutaneous nerve (S1,2,3). Look at the posterior aspect of the thigh to identify this nerve running medial to the sciatic nerve
    - Pudendal nerve (S2,3,4)
    - Superior gluteal nerve
    - Inferior gluteal nerve: the last two can be seen on the posterior aspect of the gluteal region proximal to and distal to piriformis
    - Other small branches (refer to textbook and lecture handout) are not visible

Materials: Bones of foot, foot models, prosected specimens showing ligaments and intrinsic muscles of foot, posterior abdominal wall showing lumbosacral plexus

LECTURE & NOTES: THE FOOT

FASCIA OF THE FOOT

Thin on the dorsum. Plantar fascia thickened in the centre to form Plantar aponeurosis

DORSUM OF THE FOOT :EXTENSOR DIGITORUM BREVIS

Calcaneus to proximal phalanx of big toe and tendons of ext dig longus (toes 2-4)

PLANTAR MUSCLES (Detailed attachments NOT required)

FIRST LAYER all from posterior part of calcaneus

1. ABDUCTOR HALLUCIS
2. ABD. DIGITI MINIMI
3. FLEXOR DIGITORUM BREVIS toes 2-5 - Attachment similar to Flex dig Superf in hand

SECOND LAYER muscles associated with tendons of **Flex. hall long** & **Flex dig. long.**

1. QUADRATUS PLANTAE from calcaneus to tendon of flexor digitorum longus
2. LUMBRICAL MUSCLES From FDLongus to dorsal digital expansion (Cf. hand)

THIRD LAYER Small muscles of the hallux and minimus
(flexor hallucis brevis, adductor hallucis, flexor digiti minimi brevis)

FOURTH LAYER

- PLANTAR & DORSAL INTEROSSEI (Cf. hand)
- Tendons of peroneus longus & tibialis post.

RETINACULA

SUPERIOR EXTENSOR RETINACULUM
between lower end of tibia and fibula. Tibialis ant has its own synovial sheath

INFERIOR EXTENSOR RETINACULUM
Y-shaped. Uper surface of calcaneus i) to tibial malleolus and ii) to plantar aponeurosis

FLEXOR RETINACULUM
Tip of medial malleolus to medial process of calcaneus and plantar aponeurosis.
From medial to lateral: Tibialis post, flex dig longus, post tibial Vx, tibial n, flex hall longus

SUPERIOR PERONEAL RETINACULUM Back of lat. malleolus to lat. surface of calcaneus

INFERIOR PERONEAL RETINACULUM
Continuous with inf extensor retinaculum, to lateral surface of calcaneus. Some fibres attached to peroneal trochlea, forming a septum between 2 peroneal tendons

ARCHES OF THE FOOT

LONGITUDINAL ARCHES

- MEDIAL ARCH: Calcaneus, talus, navicular, 3 cuneiforms, 3 metatarsals. Higher, more mobile. Ligaments: all ligaments on the plantar aspect, plantar aponeurosis.Muscles: TibPost, FDL, FHL, intrinsic mm of foot
- LATERAL ARCH: Calcaneus, cuboid, 2 MT. Lower, less mobile.

TRANSVERSE ARCH: foot is like a half-dome. Peroneus longus has an important function in maintaining transverse arch

NOTE:

- **INVERSION & EVERSION**: Axis (See prac notes) runs from the back of calcaneus (forwards, upwards & medially) to the sup & medial aspect of the neck of talus. Thus Inversion is associated with adduction & slight planter flexion.
- **PRONATION & SUPINATION**: Tilting of the calcaneus.
  Pronation when medial border of the foot is closer to the ground (Compare with the hand)

LUMBAR PLEXUS:

- Formed by ventral rami of L1-L4 and a branch from T12 (subcostal nerve)
- Formed in the substance of Psoas major, anterior to the transverse processes of lumber vertebrae
-

Branches:

- Iliohypogastric and ilioinguinal nerves (L1)
- Genitofemoral n (L1-2)
- Lateral cutanerous n of the thigh (L2-3)
- Femoral n (L2-4)
- Obturator nerve (L2-4)
- From L4: a branch to form lumbosacral trunk (with L5)

Relations of branches:

All branches are formed from within the substance of psoas and emerge
through its anterior surface: genitofemoral n
from its medial border at the level of pelvic brim: obturator n
from its lateral border: all the other branches.

SACRAL PLEXUS

- Formed by lumbosacral trunk and the ventral rami of S1-S4
- Located in front of the piriformis and behind the ureter & internal ilac Vx and their branches

The sacral roots emerge from the ventral sacral foramina, run on the piriformis and converge into the sciatic nerve at the lower part of the greater sciatic notch (Thus the sciatic nerve escape from the pelvic under the piriformis when viewed from the gluteal region)

The superior and inferior gluteal arteries pass through the plexus

Branches:

- Nerve to piriformis (S1-2)
- Superior gluteal nerve (L4-5 S1)
- Inferior gluteal nerve (L5 S1-2)
- Nerve to quadratus femoris and gemellus inferior (L4-5 S1)
- Nerve to obturator internus and gemellus superior (L5 S1-2)
- Posterior cutaneous nerve of the thigh (S1-3)
- Perforating cutaneous nerve (S2-3)
- Pudendal nerve (S2-4)

- *Sciatic nerve* (L4-S4), made up of the tibial nerve and the common peroneal nerve

COOCYGEAL PLEXUS (not important)

Formed by S4-5
Lies on the coccygeus muscle
Gives branches to the coccygeus and levator ani

LAB CLASS 9: VESSELS AND NERVES OF THE LOWER LIMB

LEARNING ACTIVITIES

VESSELS OF THE LOWER LIMB:

1 Observe a demonstration identifying position and extent of superior and inferior gluteal, femoral, profunda femoris, popliteal, anterior and posterior tibial and dorsalis pedis arteries. The great and small saphenous veins and the femoral vein are also indicated. The femoral sheath, femoral canal, saphenous hiatus, adductor canal and femoral rings are described. Positions of superficial and deep inguinal lymph nodes are also indicated.

2. Arteries of the thigh. Identify the **femoral** artery, note its relations with the femoral vein and nerve in the femoral triangle, and its relations with the vein and two nerves in the adductor canal. Note that it becomes popliteal artery when it passes through adductor hiatus. Try to find its descending genicular branch(es)

3. Identify the **profunda femoris**. Note that it runs deep to adductor longus. Identify its major branches:
   - Medial circumflex femoral artery: seen in the femoral triangle
   - Lateral circumflex femoral artery: seen in the femoral triangle
   - Perforating arteries that can be seen on the back of the thigh as they emerge from the adductor magnus

4. Note that blood supply to the head of the femur comes from arteries running up the neck to the femoral head from an arterial circle at the neck which if formed mainly by the 2 circumflex femoral arteries. That is why fracture of the neck of the femur can lead to avascular necrosis of the head

5. **Obturator** artery accompanies obturator nerve. It is usually removed in our prosections

6. Turn to the back of the thigh to identify the **popliteal** artery. Note the arrangement of the popliteal artery and vein and the tibial and common peroneal nerves in the popliteal fossa. Its genicular branches are difficult to find

7. In the gluteal region, try to identify the **superior** and **inferior gluteal** arteries accompanied by nerves of the same names

8. In the back of the leg, identify the **posterior tibial** artery accompanied by the tibial nerve, find the origin of the anterior tibial artery just below popliteus muscle and the **peroneal** artery which is closely related to the flexor hallucis longus.

   Follow the posterior tibial artery until it divides into **medial** and **lateral plantar** arteries. These arteries accompany nerves of the same names, the medial one runs along the meidal border of the foot, the lateral one crosses to the lateral side of the foot between muscle layers 1 and 2. Refer to lecture handouts or textbook diagrams to see how the latter form the plantar arch if you cannot find it on the specimens.

9. Look at the front of the leg prosections, retract the tibialis anterior and the extensor digitorum to find the **anterior tibial** artery accompanied by the deep peroneal nerve.

   Identify the continuation of the anterior tibial artery at the ankle: **dorsalis pedis** artery. Refer to lecture handouts or textbook diagrams to see the location of arcuate artery and its dorsal metatarsal arteries if you cannot find them on the specimens.

10. Listen to a brief demonstration of your tutor on the anastomoses around the knee joint and ankle. You only need to be aware of them, no detail knowledge of the component and location of these anastomoses is expected.

11. Identify the great and small **saphenous veins** and participate in a tutorial discussion of the venous drainage of the lower limb and the anatomy of *varicose veins*.

NERVES OF THE LOWER LIMB

12. Referring to lecture materials, review the nerves of the lower limb. This manual only list the nerves and their branches that you can identify on the specimens and is not a comprehensive review of the nerves. Identify the following nerves:
    - *Femoral* nerve and its muscular and cutaneous branches: in femoral triangle. Look for the two nerves in the adductor canal, and follow the saphenous nerve down to the medial border of the foot.
    - *Obturator* nerve: note that the adductor brevis separate its anterior from its posterior branches. Identify some muscular branches. What is the skin area supplied by the obturator nerve?
    - *Superior* and *inferior gluteal* nerves: in the gluteal region (See above)
    - *Posterior femoral cutaneous* nerve on the medial of (or sometimes posterior to) the sciatic nerve
    - *Sciatic* nerve: trace it from its emergence under the piriformis. Sometimes, the 2 components split early in the upper thigh or even in the pelvis. Identify a few muscular branches to the hamstrings and the hamstring part of adductor longus
    - *Tibial* nerve: continues the direction of the sciatic. Identify some of its muscular branches. Follow it down to the tarsal tunnel when it divides into medial and lateral plantar nerve. Compare the medial plantar nerve to median nerve and the lateral plantar to ulnar nerve in the hand, their pattern of innervation is only slightly different from that in the hand. Review the relations of structures passing under the flexor retinaculum
    - *Common peroneal* nerve: observe it crossing the neck of the fibula where it can be injured. You may see the sural nerve which receives contribution from both the tibial and common peroneal nerve. It eventually runs down the lateral border of the foot
    - *Superficial peroneal* nerve can be found between the two peronei. Follow it to the lower third of the leg when it becomes subcutaneous and innervate the skin of most of the dorsum of the foot
    - *Deep peroneal* nerve can be found on the interosseous membrane when you separate the tibialis anterior from the extensors (See above). You may find the cutaneous branch which lies on the lateral side of the dorsalis pedis artery and supplies the skin between the 1st and 2nd toes

13. Identify major arteries and vfeins of the lower limb on an giograms provided.

REVIEW THE MOTOR AND CUTANEOUS SUPPLIES OF THE NERVES

Refer to lecture materials and textbook, draw up in your own time a summary of the muscle groups and skin areas supplied by the nerves of the lower limb.

Materials: Deep thigh prosections showing the femoral artery and branches, free lower limbs, superficial and deep leg dissections, plastinated specimens of the foot.

DERMATOMES: Revise the pattern of dermatomes, i.e. the areas of skin supplied by individual spinal nerves. Note that you sit on S3, and walk on S1.

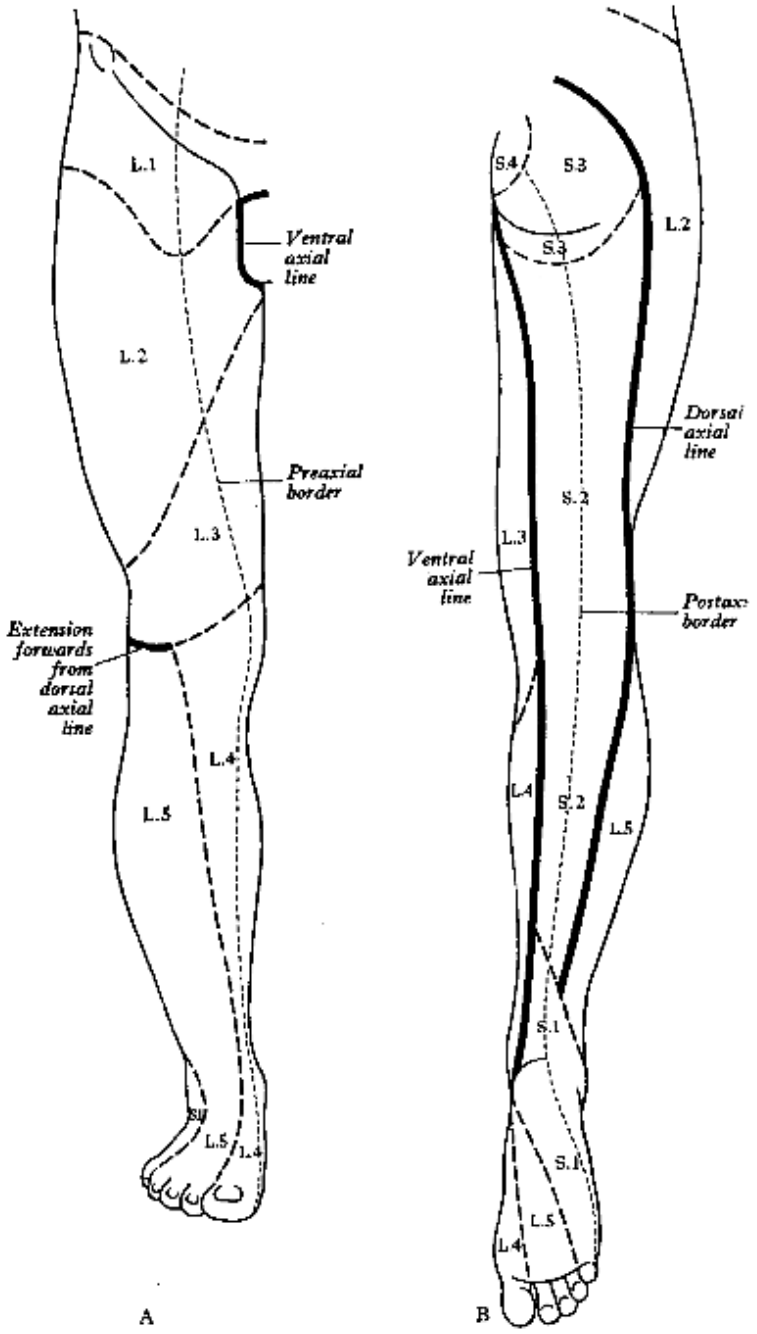

NERVES OF THE LOWER LIMB

LATERAL FEMORAL CUTANEOUS N.

FEMORAL N.

- N to iliacus (in the pelvis)
- N to pectineus, sartorius, quadriceps
- Femoral cutaneous nn (intermediate, medial)
- *Saphenous n.*
  ---> infrapatellar branch (skin down to the medial side of foot)

OBTURATOR N.

Passes through obturator canal, pierces obt. externus, "rides" add brevis

- Branches to obturator externus, gracilis, adductors
- Cutaneous brs: medial side of thigh

POSTERIOR FEMORAL CUTANEOUS N.

Lies posterior or medial to sciatic n.

- Skin of buttocks, back of thigh & upper leg

NERVES to Quadratus femoris & Obturator internus.

Inf Gluteal n. (to Glut. Max.) & **Sup Gluteal n.** (to Glut. Med & Min, Tensor F.Lata)

SCIATIC NERVE

Passes through greater sciatic foramen below piriformis, lies midway between greater trochanter & ischial tuberosity, then over Obt. int, gemelli & Quad fem.

Most often divides into 2 terminal brs near apex of popliteal fossa.

- Supplies hamstrings and ischial head (hamstring part) of add magnus
- Terminal brs: Tibial n. & Common peroneal n.

TIBIAL NERVE

Descends almost vertically, accompanies popliteal & post tibial aa.

Lies deep to soleus, divides deep to flexor retinaculum into 2 terminal brs

- Contributes to *Sural n.* (with a br from common peroneal n.): skin on lateral & post aspects of leg, down to lateral side of foot
- Supplies all muscles of posterior compartment of the leg
- Terminal brs: Medial plantar (Cf median n.)
  Lateral plantar (Cf ulnar n.)

COMMON PERONEAL N.

Winds around neck of fibula. When deep to superior part of peroneus longus, divides into 2 terminal brs

- *Lateral sural n.*: skin on lateral side of calf
- Communicating branch to *sural* n.
- Terminal brs: Deep & superficial peroneal nn.

Deep peroneal n.

Enters ant compartment, runs on interosseous membrane, accompanied by ant tibial a., then deep to extensor retinaculum into the dorsum of the foot.

- Muscles of ant compartment
- Skin between big & 2nd toes

Superficial peroneal n.

Runs between 2 peronei, becomes subcutaneous in the distal third of the leg then to the dorsum of the foot.

- Peronei
- Skin of lateral side of leg, ankle, dorsum of foot

SUMMARY OF MYOTOMES

HIP :	Flexion	L2-3 (also add, med.rot.)	**ANKLE**:	Dorsiflexion L4-5	
	Extension	L4-5 (also abd & lat rot.)		Plantar flexion S1-2	
KNEE:	Extension	L3-4		Inversion L4	
	Flexion	L5-S1		Eversion L5-S1	

DERMATOMES

- Around inguinal region L1
  Front of knee L3 - Over tibia is L4, over fibula is L5
  Foot: medial side L5, lateral side S1
- *"One walks on S1, sits on S3 (around the anus)*
  S2 narrow strip up the middle of the calf and hamstrings."

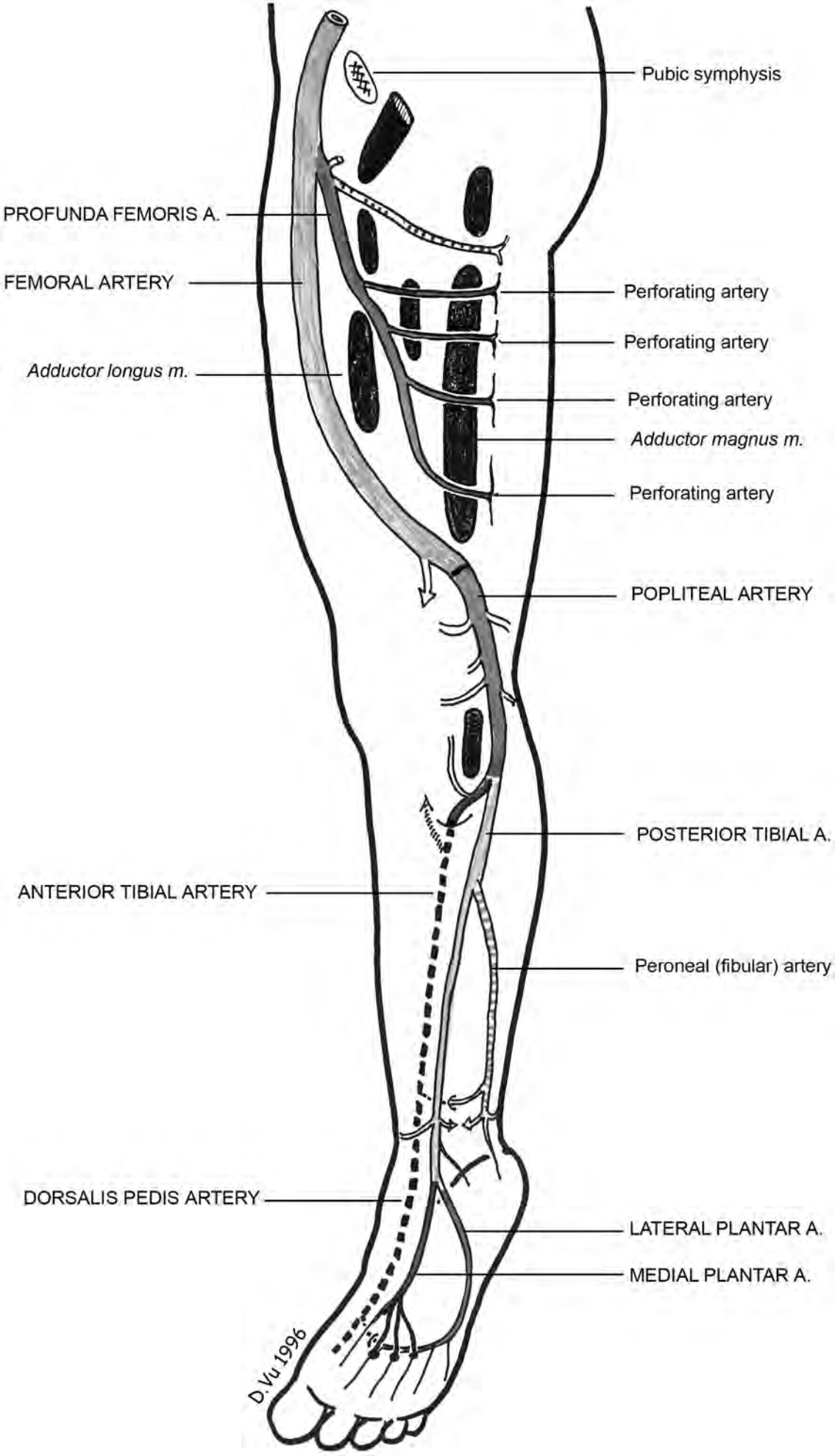
Pubic symphysis
PROFUNDA FEMORIS A.
FEMORAL ARTERY
Perforating artery
Perforating artery
Adductor longus m.
Perforating artery
Adductor magnus m.
Perforating artery
POPLITEAL ARTERY
POSTERIOR TIBIAL A.
ANTERIOR TIBIAL ARTERY
Peroneal (fibular) artery
DORSALIS PEDIS ARTERY
LATERAL PLANTAR A.
MEDIAL PLANTAR A.
D.Vu 1996

FUNCTIONAL NOTES:
FUNCTIONAL MUSCLE GROUPS

HIP JOINT

- Angle of the neck with axis of the shaft: 120-125 degrees. Coxa vara predisposes to dislocation
- Anteversion of the neck (20 degrees between axis of the neck and frontal plane. Increased anteversion predisposes to anterior dislocation

HIP FLEXORS

They lie in the frontal plane, ANTERIOR to the centre of the hip joint

- Psoas and Iliacus
- Tensor fasciae latae
- Sartorius
- Rectus femoris

Others are not as efficient flexors and also produce adduction/abduction or medial/lateral rotation:

- Pectineus
- Adductors longus and brevis
- Gracilis
- The most anterior fibres of all 3 gluteal muscles

HIP EXTENSORS

They lie in the frontal plane, POSTERIOR to the centre of the hip joint

- Gluteal muscles (which also produce abduction)
- Gluteus maximus (which is only important when running or walking up a slope, it is not involved in normal walking on flat ground)
- Most posterior fibres of gluteus medius and gluteus minimus
- Hamstrings (which also produce adduction)

When the pelvis is tilted posteriorly, the iliofemoral ligament stabilises the pelvis
When the pelvis is tilted anteriorly, it is stabilised by the hamstrings, then hamstrings AND gluteal muscles.

HIP ABDUCTORS

- The most powerful abductor is gluteus medius (Trendelenburg's sign)
- Tensor fasciae latae and gluteus maximus (by pulling on fascia lata on the lateral side of the thigh)
- Gluteus minimus
- Piriformis

HIP ADDUCTORS

Powerfull adductors are:

- Three adductors
- Gracilis
- The fibres of Gluteus maximus which are attached to gluteal tuberosity

Weaker adductors are:

- Hamstrings
- Pectineus
- Quadratus femoris
- Obturator externus
- Obturtor internus and gemelli

LATERAL ROTATORS OF THE HIP JOINT

- Pelvitrochanteric muscles (6)
- Gluteus maximus
- Posterior fibres of gluteus medius and minimus
- Quadratus femoris

MEDIAL ROTATORS OF THE HIP JOINT

NOTE: The axis of rotation of the thigh is a line joining the centre of the femoral head and the centre of the femoral condyle! For example: relate the adductor longus with this axis, and it is obvious the muscle medially rotates the thigh (not laterally rotates it as it appears to do at first glance!)

- Gluteus minimus
- Anterior fibres of gluteus medius
- Tensor fasciae latae
- Hamstring part of adductor magnus

INVERSION OF MUSCLE ACTIONS

Actions of a muscle depend on its relative position with the axis of the movement

Example 1: Piriformis is a lateral rotator. But when the femur is flexed, it becomes a pur abductor

Example 2: Quadratus femoris flexes the hip when the femur is extended and extends it when the femur is flexed

KNEE JOINT

KNEE FLEXORS

- Hamstrings
- Gracilis
- Sartorius
- Gastrocnemius
- Popliteus

NOTE:
Monoarticular muscles (eg short head of biceps) always has the same efficiency.
Efficiency of *biarticular* muscles depends on the position of one joint. Eg. the more the hip is flexed (stretching the hamstrings), the more efficient the hamstrings are as flexors of the knee.

MEDIAL ROTATORS OF THE KNEE

Muscles attaching to the medial aspect of the tibia:

- Semimembranosus
- Sartorius, gracilis, semitendinosus (attaching as pes anserinus)
- Popliteus

LATERAL ROTATORS OF THE KNEE

- Biceps (attaching to the fibular)
- Tensor fasciae latae (attaching to the iliotibial tract)

ANKLE JOINT

DORSIFLEXORS

Muscles of the anterior compartment of the leg

PLANTAR FLEXORS

- Muscles of the posterior compartment of the leg
- Peroneus longus and peroneus brevis

INVERSION

- Muscles passing through tarsal tunnel (Muscles of anterior compartment of the leg)
- Tibialis posterior

EVERSION

- Muscles of the lateral compartment of the leg (Peroneus longus & P. brevis)
- Extensor digitorum longus
- Peroneus tertius

LAB CLASS 10: SURFACE ANATOMY (Courtesy of Dr Toby Arnold & Prof. David Tracey)

Instructions: Swimming costumes or leotards should be worn. Work in mixed groups of three or four students. One student should be a model, one should mark the features with a grease pencil, and one should read out the instructions.

Identify each of the following:

A. HIP and THIGH:

1) Iliac crest and its two ends, the anterior and posterior superior iliac spines (ASIS & PSIS). The latter is indicated by a dimple. The tubercle of the iliac crest is a prominence of the outer lip, 5 cm posterior to the anterior spine.
2) Anterior inferior iliac spine (AIIS), felt deeply, 2.5 cm below and medial to the superior spine.
3) Pubic symphysis, pubic crest and pubic tubercle. The pubic bones meet in the midline at the symphysis where they are united by fibrocartilage. On each side of the symphysis, the pubic crest can be felt on the upper border of the pubis extending laterally for about 3 cm on each side as far as the pubic tubercle.
4) Pubic arch. This can be felt below the symphysis, in the male by palpation from the scrotum, in the female immediately below the mons pubis in front of the clitoris. It is formed by the diverging inferior rami of the pubic bones of the two sides.
5) Head of the femur is deep to the midinguinal point: midway between the ASIS and the pubic symphysis. The femoral head can be felt moving when the limb is rotated.
6) Femoral artery can be felt pulsating on firm pressure just distal to the midinguinal point. Just lateral to it is the femoral nerve.
7) Greater trochanter of the femur. Prominent lateral convexity at the junction of buttock and thigh. The top of the greater trochanter should be on line between the ASIS and ischial tuberosity.
8) Ischial tuberosity. Above the medial part of the gluteal sulcus. (Sit on your fingers to palpate).
9) Sacrum and coccyx. The tip of the coccyx can be felt in the upper part of the gluteal cleft, the deep groove that separates the buttocks. Above this level there is a triangular flattened area which corresponds to the greater part of the sacrum.

Note that the summit of the greater trochanter is situated approximately at the same level as the centre of the hip joint, the upper margin of the symphysis pubis, and the tip of the coccyx.

10) Iliotibial tract, a vertical thickening of the deep fascia on the lateral side of the thigh, best felt when the hip is flexed and the knee extended. Its anterior edge is marked by a line from the ASIS to the lateral edge of the patella, and its posterior edge by a line from the tubercle of the iliac crest to the furrow descending parallel to the anterior edge and about 3-5 cm behind it. The furrow indicates the lateral intermuscular septum.
11) Quadriceps muscle: flex the limb at the hip and extend it at the knee. Identify rectus femoris, vastus lateralis, and vastus medialis.
12) Sartorius muscle: flex the laterally rotated limb at the hip. Sartorius runs from ASIS to the medial side of the knee, but is difficult to see.
13) Tensor fasciae latae muscle, forming a vertical bulge lateral to the ASIS, where the sartorius originates. In the acute angle between these two muscles, feel the tendon of rectus femoris passing down on the capsule of the hip joint.To palpate tensor fasciae latae, plant the foot on the ground and attempt to medially rotate it.
14) Adductor longus tendon, felt descending from the angle between the pubic crest and symphysis. It is more easily felt if the thigh is slightly flexed, and then adducted against resistance.
15) Gracilis and adductor magnus as above, difficult to palpate.
16) Hamstring muscles: flex the knee against resistance when lying prone (face downwards). The semitendinosus emerges together with the long head of biceps femoris, at the middle of the gluteal fold. Just above the knee they form the triangular upper border of the popliteal fossa. At the medial border of the popliteal fossa, the tendon of semimembranosus is more medial, broader and deeper than the tendon of semitendinosus, which is more cordlike and superficial. On the lateral side of the knee, biceps femoris tendon can be seen attaching to the head of the fibula.
17) Gluteal muscles: gluteus maximus is superficial and forms the prominence of the buttock. With the subject lying face down, extend the hip joint against resistance. The lower margin of the muscle can be palpated below the lateral part of the gluteal fold. Gluteus medius lies superficially in the floor of the gluteal depression, above the greater trochanter. Together with tensor fasciae latae, it covers the deeper gluteus minimus. Abduct the hip (or rotate the thigh medially) against resistance and feel the muscle.
18) Sciatic nerve. Runs from a point midway between the greater trochanter and ischial tuberosity down the middle of the posterior thigh.

B. KNEE and LEG:

1) Medial femoral condyle, the rounded prominence on the medial side of the knee, more obvious when the knee is flexed. Its most prominent point, the medial epicondyle, is near the posterosuperior edge.
2) Lateral femoral condyle, a less obvious prominence surmounted by the lateral epicondyle.
3) Patella, a large sesamoid bone forming the rounded prominence in front of the knee when the leg is extended. When standing the patella is freely movable from side to side, i.e. the quadriceps is slack. When the leg is flexed, the patella moves distally, disclosing the patellar surface of the femur, a broad visible groove between the condyles. Remember the base is proximal, the apex distal.
4) Adductor tubercle of the femur, about 1 cm above the medial epicondyle. Place the tip of your right index finger on the medial end of the base of your left patella; the adductor tubercle can be felt with the little finger.
5) Tibial tuberosity, connected to the apex of the patella by the patellar ligament.
6) Medial tibial condyle, superomedial to the tuberosity.
7) Lateral tibial condyle, somewhat more prominent, superolateral to the tuberosity.
8) Line of the knee joint, felt as a transverse sulcus between femoral and tibial condyles on each side.
9) Medial and lateral collateral ligaments on either side of the knee joint, taut in extension.
10) Anterior border of tibia, subcutaneous from tibial tuberosity above to the front of medial malleolus below.
11) Head of the fibula, level with the tibial tuberosity and lateral to the lateral tibial condyle. Note the lack of movement at the proximal tibiofibular joint.
12) Common peroneal nerve, tucked under the medial edge of the biceps tendon. It can be rolled against the lateral side of the head of the fibula.
13) Popliteal artery can be felt pulsating in the midline of the upper half of the popliteal fossa with the model prone and the knee passively flexed to about 45 degrees.
14) Medial and lateral gastrocnemius muscles: their converging heads form the lower border of the diamond-shaped popliteal fossa.
15) Soleus muscle can be seen extending further laterally and inferiorly than the gastrocnemius muscles.
16) Peroneus longus and brevis stand out just anterior to soleus, when the model stands on his toes (plantar flexion), or when the foot is everted against resistance. They cover the lateral side of the fibula.

C. ANKLE and FOOT:

Medially:

1) Medial malleolus, whose medial surface is subcutaneous.
2) Sustentaculum tali: just below the medial malleolus. You may be able to feel the tendon of flexor hallucis longus when the great toe is flexed.
3) Tuberosity of the navicular: the prominence 3 cm antero-inferior to the medial malleolus, about halfway down the medial surface of the foot. Provides distal attachment for tibialis posterior.

Remember: AHANDT

Achilles tendon, Flexor hallucis longus, Posterior tibial artery, Tibial nerve, Flexor digitorum longus, Tibialis posterior.

Laterally:

4) Lateral malleolus; its tip is 2cm below and 1 cm behind that of the medial malleolus. Note the triangular subcutaneous lateral surface. The apex is above, where it provides an attachment for the anterior intermuscular septum.
5) Peroneal trochlea: a small elevation on the calcaneus about 2cm below the tip of the lateral malleolus. It separates the tendons of peroneus longus (posteriorly) and peroneus brevis (anteriorly). Difficult to palpate.
6) Tuberosity of the 5th metatarsal is about 3cm anterior to the peroneal trochlea; provides attachment for peroneus brevis.
7) With the foot resting on the ground, dorsiflex the toes and note the hollow that appears immediately in front of the lateral malleolus.
8) Head of the talus can be felt antero-medially in this hollow, articulating with the navicular deep to the extensor tendons.
9) Body of the talus is felt in slight passive dorsiflexion, just anterior to the distal edge of the front of the tibia. The two are separated by the line of the talocrural (ankle) joint.

Dorsally:

10) Extensor digitorum brevis: its belly forms the anterior boundary of the hollow mentioned above. In some individuals, the medial part of the muscle is distinguishable as extensor hallucis brevis.
11) Peroneus tertius: in active dorsiflexion, its tendon can be seen or felt on the medial border of the hollow.
12) Peroneus longus and brevis: the muscle bellies are just in front of the lateral edge of soleus. The tendons of these muscles stand out in plantar flexion and eversion, from behind the lateral malleolus to the lateral edge of the foot. That of peroneus brevis passes above the peroneal trochlea to the tuberosity of the 5th metatarsal; that of peroneus longus passes below the trochlea to the edge of the foot, where it winds under the cuboid, obscured by abductor digiti minimi.

Remember: AHANDT

13) Tibialis anterior: its tendon provides the upper boundary of the hollow in front of the medial malleolus. Prominent in resisted dorsiflexion and inversion.
14) Extensor hallucis longus tendon
15) Dorsalis pedis artery (continuation of anterior tibial a.)
16) Peroneal nerve: the superficial peroneal lies superficial to tendons of EDL, deep peroneal lies deep to them.
17) Extensor digitorum longus tendons
18) Peroneus tertius tendon (see #11 above).

Finally note the superficial veins, arising from the

19) Dorsal venous arch:
20) Great saphenous vein, running anterior to the medial malleolus, and emptying into the femoral vein in the femoral triangle
21) Small saphenous vein, running posterior to the lateral malleolus, and emptying into the popliteal vein a little above the knee joint.

Modified from notes by Dr. M. (Toby) Arnold

D. DERMATOMES

Revise the dermatomes; make sure that you can draw a rough sketch of the anterior and posterior aspect of the lower limb with the dermatomes and cutaneous distributions of cutaneous nerves such as the sural and saphenous.

Materials: Video of surface anatomy, lower limb; skin pencils and skeletons.

CROSS SECTIONAL ANATOMY

This lab class may be completed in your own time, using the cross-sectional anatomy program available on computers in the museum and room 111. Another useful tool is one of the atlases of sectional anatomy, such as:

McGrath & Mills "Atlas of Sectional Anatomy" (Karger, 1984).

Ellis, Logan & Dixon "Human Cross-Sectional Anatomy - Atlas of body sections and CT images" (Butterworth-Heinemann, 1991).

Spitzer & Whitlock "Atlas of the Visible Human Male - Reverse engineering of the human body" (Jones & Bartlett).

Identify as many of the following musculoskeletal features as you can. The description assumes that you navigate from above downwards, and only describes structures which have not been mentioned at previous (upper) levels.

Vertebral column. Scan down the vertebral column from C7-L5, noting how the size of the vertebral body increases from above down. Note also the relation between the size of the vertebral canal and that of the spinal cord at different levels of the vertebral column, and the orientation of facet joints. In particular, note the spinal nerves (C7, 1280); orientation of facet joints in the thoracic spine (T9-T10 IVD, 1490; T11-T12 IVD 1153); costovertebral joints (T10, 1500). Note how the the orientation of the facet joints has changed in the lumbar region (L3, 1665) so that the superior articular facets face medially rather than laterally, preventing axial rotation.

Abdomen

LV1 (1596) Note rectus abdominis (RA), external oblique muscle, and transversus abdominis (deep to RA but unlabelled). Note latissimus dorsi and posteriorly the psoas, quadratus lumborum and postvertebral muscles including erector spinae and transversospinalis.

LV2 (1629) As above: note also the orientation of the facet joint, with the inferior articular process of LV1 (facing laterally).

LV3 (1665) Note that the external and internal oblique as well as transversus abdominis are all clearly seen. Again, note the facet joint between L2 and L3.

Pelvis

LV5 (1755) The lamina of L5 can be seen, as can the ilium with gluteus medius externally and iliacus internally. Psoas and other abdominal muscles can still be seen, as can the postvertebral muscles.

L5-S1 (1775) Note S1 with the sacroiliac joint and the sacroiliac ligament. Note also the upper part of gluteus maximus.

SV2 (1797) The sacroiliac joint and sacroiliac ligament can be seen more clearly. Note also the three gluteal muscles (maximus, medius and minimus) and the iliopsoas muscle.

Co1 (1850) At this level, the gluteal muscles are clear and obturator internus can be seen.

Co2 (1875) Note the hip joint with the acetabulum and head of femur. The ligament of the head of the femur can even be seen in the fovea! Note also the femoral artery and vein lying on iliopsoas, with sartorius, rectus femoris and tensor fascia latae laterally, and pectineus medially. Deep to the gluteal muscles, some of the lateral rotators can be seen - superior gemellus, obturator internus, and the tendon of piriformis.

Co3 (1895) The neck and greater trochanter of the femur can be seen, with iliopsoas, rectus femoris, tensor fascia latae and sartorius anteriorly. Note the pubis and pubic symphysis, obturator internus medial to the ischium, and inferior gemellus behind the neck of the femur.

Materials: Cross sectional anatomy program (Anatomy Museum).